

CHRONIC PANCREATITIS WITH FOCAL MASS VS. PANCREATIC ADENOCARCINOMA - DIFFERENTIAL DIAGNOSIS

Yessica Costa
Luísa Costa Andrade

Coimbra, 28th April 2014

CHRONIC PANCREATITIS

CHRONIC PANCREATITIS

- Continuing inflammatory disease characterized by irreversible damage of the pancreas resulting in progressive impairment of both endocrine and exocrine functions.
- The incidence of CP → 3.5 - 10.0 / 100000 people in industrialized countries.
- Multiple etiological factors
 - alcohol abuse (70%)
 - gallstone biliary disease (20%)

CHRONIC PANCREATITIS ETIOLOGY

Potential etiologic factors of chronic pancreatitis

Toxic	Alcohol, cigarette smoking, drugs (e.g. glucocorticosteroids, azathioprine, hydrochlorothiazide, estrogens, valproic acid, phenacetin)
Metabolic	Hyperlipidemia, hypercalcemia, hyperparathyroidism, chronic renal failure
Infectious	Mumps, coxsackie virus infection, HIV, cryptosporidium
Obstruction of the main pancreatic duct	Gallstones, neoplasms (pancreatic/periampullary), post-traumatic scarring, Sphincter of Oddi dysfunction, pancreas divisum, pancreas annulare
Autoimmune	Immunoglobulin G4-related sclerosing disease
Genetic / hereditary	CFTR mutation (cystic fibrosis), PRSS1 mutation, SPINK1 mutation
Recurrent acute pancreatitis	Postnecrotic, recurrent acute pancreatitis
Other	Idiopathic, tropical pancreatitis, radiation therapy, vascular disease (polyarteritis nodosa, severe arteriosclerosis)

DIAGNOSIS OF CP

- 3 Hallmarks:
 - **Clinical symptoms**
 - diabetes, steatorrhea, chronic recurrent abdominal pain
 - **Imaging findings**
 - **Assessment of pancreatic function**
- Poor correlation
 - Patients with severe exocrine insufficiency may present a structurally normal pancreatic parenchyma and vice-versa.

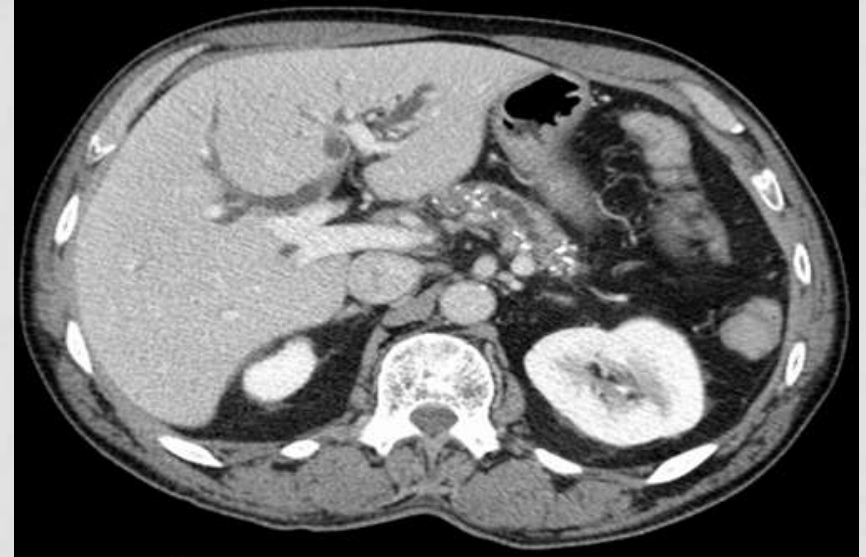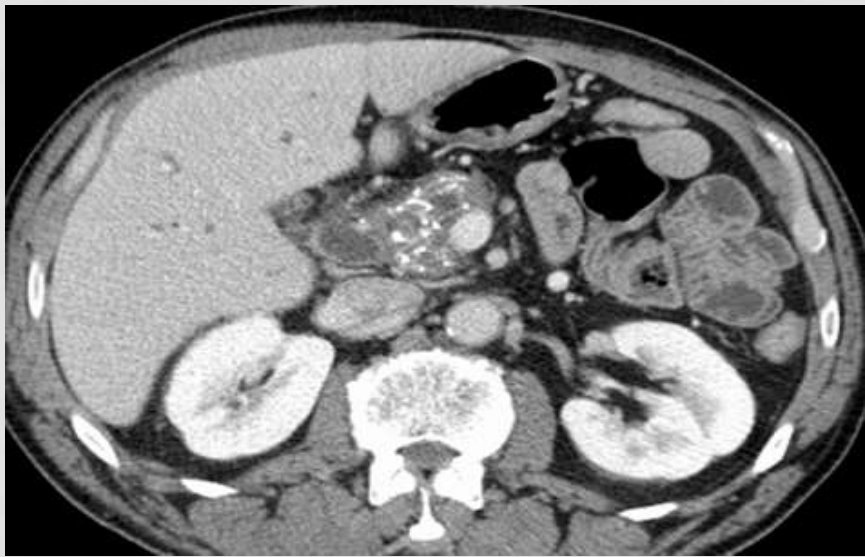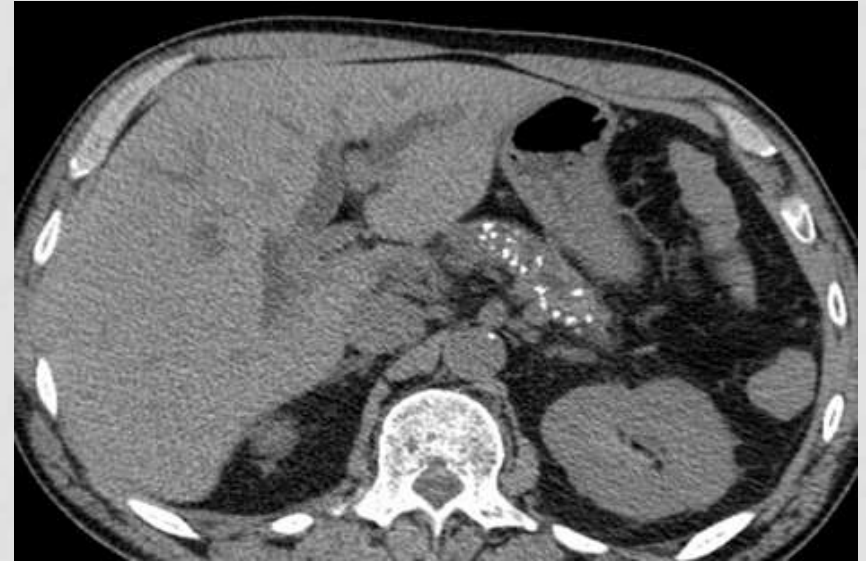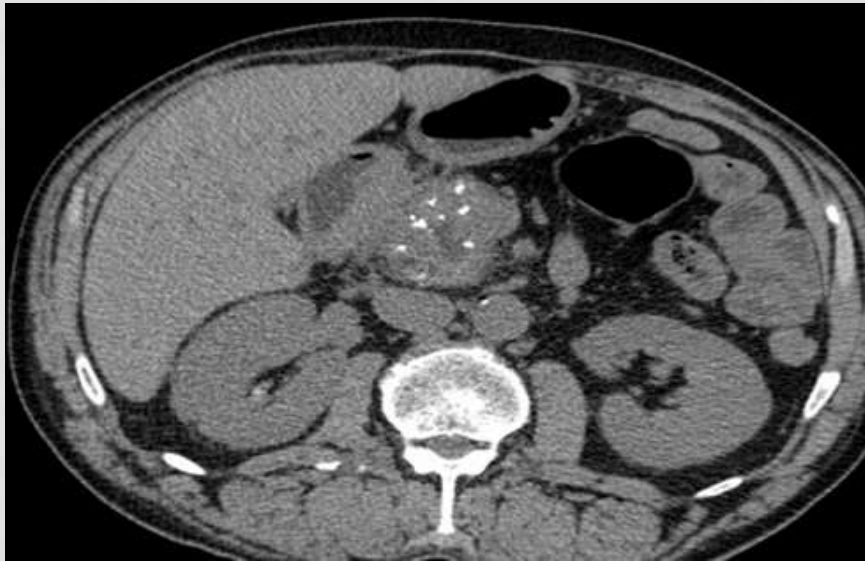
COMPUTED TOMOGRAPHY (CT)

- First imaging method in assessing patients with CP
 - Main disadvantages → Radiation exposure /Lack of functional evaluation component.

Computed Tomography Protocol	<ul style="list-style-type: none">• Unenhanced• Arterial phase• Parenchymal phase• Portal venous phase	<ul style="list-style-type: none">• Detection of calcifications• Arterial mapping for surgical planning, arterial complications of CP• Assessment of pancreatic parenchyma, detect hypovascular lesions, venous complications of CP, pseudocysts• Evaluation of pancreatic duct and vascular structures
------------------------------	---	--

CT IMAGING FINDINGS

- **Duct dilatation** (up to 68%)
 - Dilatation of the **main pancreatic duct or side branches**
 - Ductal contour may be smooth, beaded or irregular
- **Parenchymal atrophy** (54%)
 - 22% of patients with exocrine insufficiency might not show atrophy in CT
- **Intraductal or scattered parenchymal calcifications** (50%)
 - Parenchymal calcifications → +++ head of the pancreas
 - Variable size and morphology (punctuate, stippled or coarse)
 - **Intraductal stones** → most reliable sign of chronic pancreatitis.



FOCAL ENLARGEMENT

- Differential diagnosis with ductal adenocarcinoma
- **Findings suggesting chronic pancreatitis**
 - Visualization of the main pancreatic duct penetrating the mass with regular stenosis - "**penetrating duct sign**"
 - The **ductal dilatation is less severe** and more **irregular**, with multiple ductal strictures and dilatation of side branches
 - **Intraductal or scattered parenchymal calcifications**
 - **Absence of clear demarcation between the focal mass and the parenchyma**

AUTOIMMUNE PANCREATITIS

AUTOIMMUNE PANCREATITIS (AIP)

- Immunoglobulin G4 (IgG4) systemic disease
 - rare form of non-obstructive and noncalcifying chronic pancreatitis associated with an autoimmune inflammatory process.
- Association with other autoimmune disease (30%)
 - Sjogren syndrome, primary biliary cirrhosis, primary sclerosing cholangitis, Crohn disease, systemic LE, and retroperitoneal fibrosis

AIP

- Variable clinical presentation
- Mean age of presentation → 60 years (ranging from 14 to 85 years)
- Clinically and histologically AIP can be classified as:
 - **Predominant lobular involvement (AIP-PL or type 1)** - predominant lobular inflammation, is a systemic disease, presents with higher number of IgG4 positive cells and is most commonly seen in Asian and males.
 - **Predominant ductal involvement (AIP-PD or type 2)** - characterized by granulocyte epithelial lesions in the pancreas without systemic involvement, presenting commonly as a **pseudotumor** and is seen in the Western population

PATTERNS OF AIP:

- **Diffuse** (most common)
 - The most common, presenting with **sausage like parenchymal enlargement** seen in 40% to 60% of patients
 - The **pancreatic contour becomes featureless and effaced**
- **Focal** (less common)
 - Well-defined mass often involving the pancreatic head and mimicking pancreatic adenocarcinoma. **Upstream dilatation may be seen, however it is less severe**
- By itself **imaging findings are non-diagnostic**

JAPANESE SOCIETY OF PANCREAS

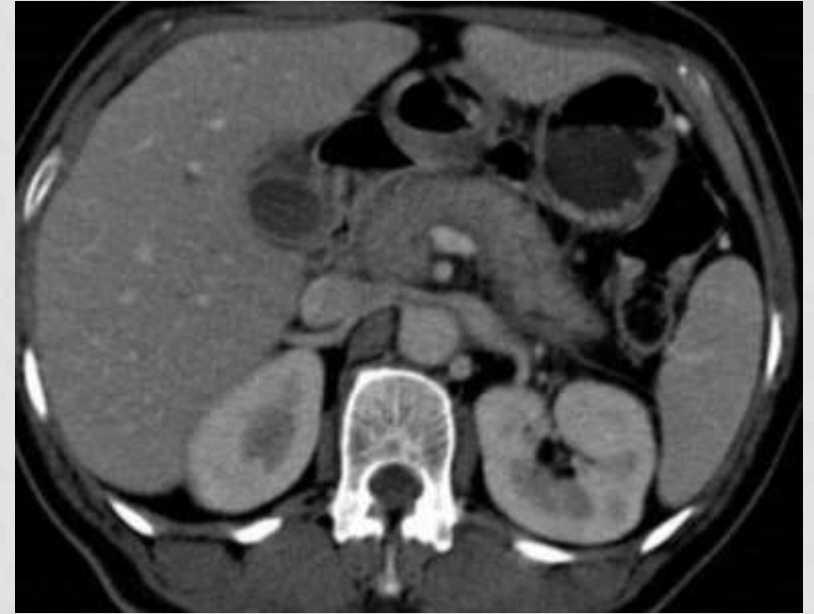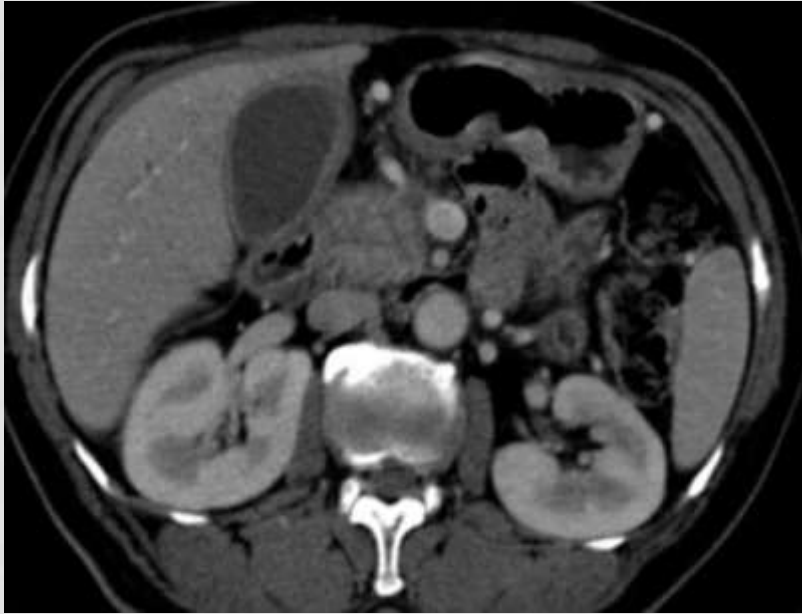
CRITERIA FOR AUTOIMMUNE PANCREATITIS

1) Typical imaging	Diffuse or segmental narrowing of the pancreatic duct with irregular wall and diffuse or localized enlargement of pancreas on US, CT and MR imaging
2) Serology	Autoantibodies (antinuclear antibodies and rheumatoid factor), elevated γ -globulins, or IgG or IgG4
3) Histopathology	Marked intralobular fibrosis and prominent infiltration of lymphocytes and plasma cells in the periductal area, occasionally with lymphoid follicles in the pancreas

Diagnosis is established when criteria 1 with criteria 2 or 3 are present

CT IMAGING FINDINGS

- Diffuse sausage-like enlargement of pancreas
- Focal swelling
- Loss of fatty lobulation
- Enhancement is variable → less enhancement
- Low-attenuation halo surrounding pancreas
- Diffuse or segmental narrowing of pancreatic duct
- Strictures of common bile duct and +/- intrahepatic ducts (indistinguishable from primary sclerosing cholangitis)



Diffuse enlargement of pancreas
Less enhancement
Loss of normal fatty lobulation
Discrete low-attenuation halo in pancreatic tail

FOCAL ENLARGEMENT

- Differential diagnosis with ductal adenocarcinoma
- **Findings suggesting autoimmune pancreatitis**
 - Lack or less severe of upstream pancreatic ductal dilatation;
 - Absence of parenchymal atrophy, vascular encasement and metastasis;
 - Extrapancreatic diffuse changes related with IgG4 systemic disease;
 - Usually has good response to steroid therapy

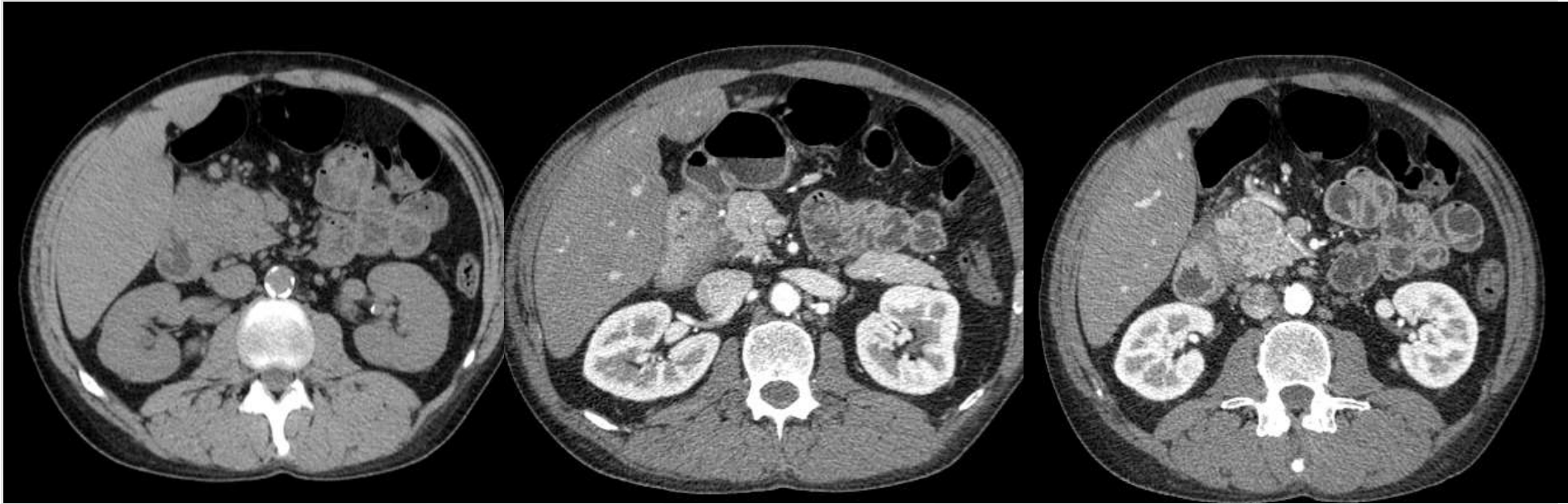
PARADUODENAL PANCREATITIS (GROOVE PANCREATITIS)

GROOVE PANCREATITIS

- Uncommon chronic pancreatitis
 - Occurs in and around the duodenal wall near the minor papilla
 - **Paraduodenal pancreatitis** → includes cystic dystrophy of the duodenal wall and paraduodenal wall cysts
- **Three patterns:**
 - Pure (the head of the pancreas is spared)
 - Segmental (the pancreatic head and the ducts are affected)
 - Nonsegmental (secondary to established chronic pancreatitis)

CT IMAGING FINDINGS

- Ill-defined soft-tissue within the pancreaticoduodenal groove, with or without delayed enhancement
- Duodenal wall thickening, with or without luminal stenosis
- Cystic changes of the duodenal wall



ill-defined soft-tissue mass within the pancreaticoduodenal groove
Duodenal wall thickening

FOCAL ENLARGEMENT

- Differential diagnosis with ductal adenocarcinoma
- **Findings suggesting Groove Pancreatitis**
 - The presence of cysts within the lesion and thickening of duodenal wall
 - Smooth and long narrowing of the main pancreatic duct
 - Absence of vascular invasion

PANCREATIC ADENOCARCINOMA



PANCREATIC ADENOCARCINOMA

- 85-95% pancreatic malignancies
- 4^a cause of cancer-related deaths
- 60-80 years of age
- M:F 2:1
- Location:
 - 60-70% pancreatic head
 - 10-20% body
 - 5-10% tail
 - 5% diffuse

PANCREATIC ADENOCARCINOMA

- Nonresectable (75%)
 - 85% with methastatic disease (liver and peritoneum)
- CT
 - Detection of the tumor
 - Assessment of ressectability

Table 1
NCCN Practice Guidelines in Oncology:
Criteria for Defining the Resectability Status
of Pancreatic Adenocarcinoma

Resectable

- No distant metastases
- No SMV or PV abutment, distortion, tumor thrombus, or venous encasement
- Clear fat planes around the CA, SMA, and HA

Borderline resectable

- No distant metastases
- Venous involvement of the SMV or PV consisting of tumor abutment with or without impingement and narrowing of the vessel lumen
- Encasement of the SMV or PV but without encasement of the nearby arteries
- Short-segment venous occlusion resulting from either tumor thrombus or encasement but with suitable vessel proximal and distal to the area of tumor involvement, allowing safe resection and reconstruction
- Gastroduodenal artery encasement up to the HA with either short-segment encasement or direct abutment of the HA, without extension to the CA
- Tumor abutment of the SMA $\leq 180^\circ$ of the circumference of the vessel wall

Unresectable

Pancreatic head

- Distant metastases
- SMA encasement $>180^\circ$, any CA abutment
- Unreconstructible occlusion of the SMV or PV
- Aortic invasion or encasement

Pancreatic body

- Distant metastases
- SMA or CA encasement $>180^\circ$
- Unreconstructible occlusion of the SMV or PV
- Aortic invasion

Pancreatic tail

- Distant metastases
- SMA or CA encasement $>180^\circ$

Nodal status

- Metastases to lymph nodes beyond the field of resection

CT IMAGING FINDINGS

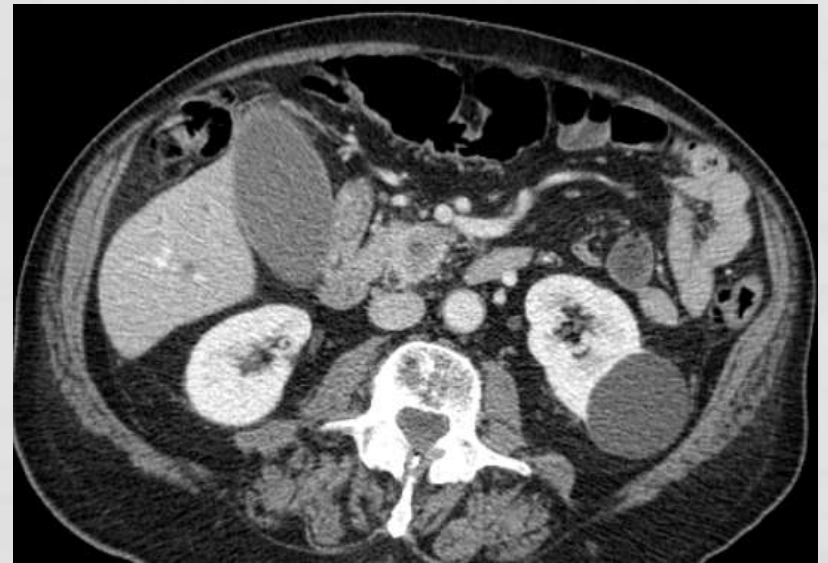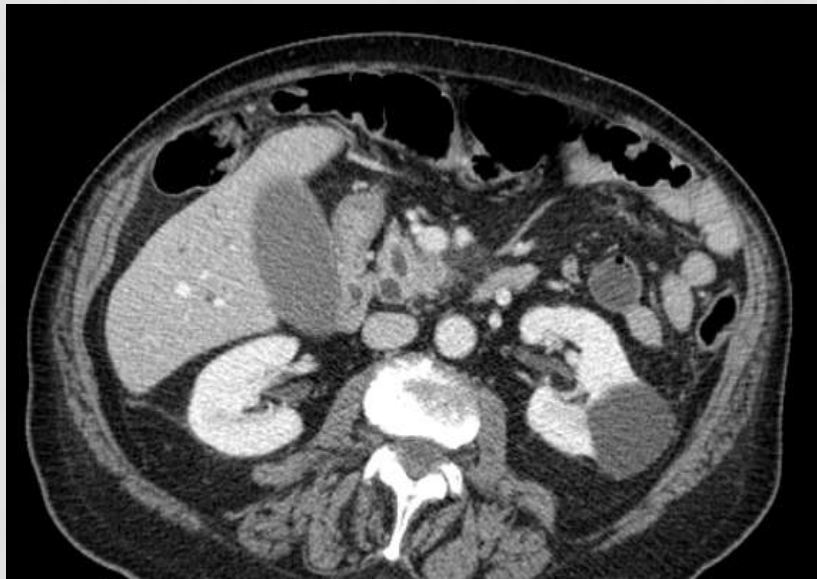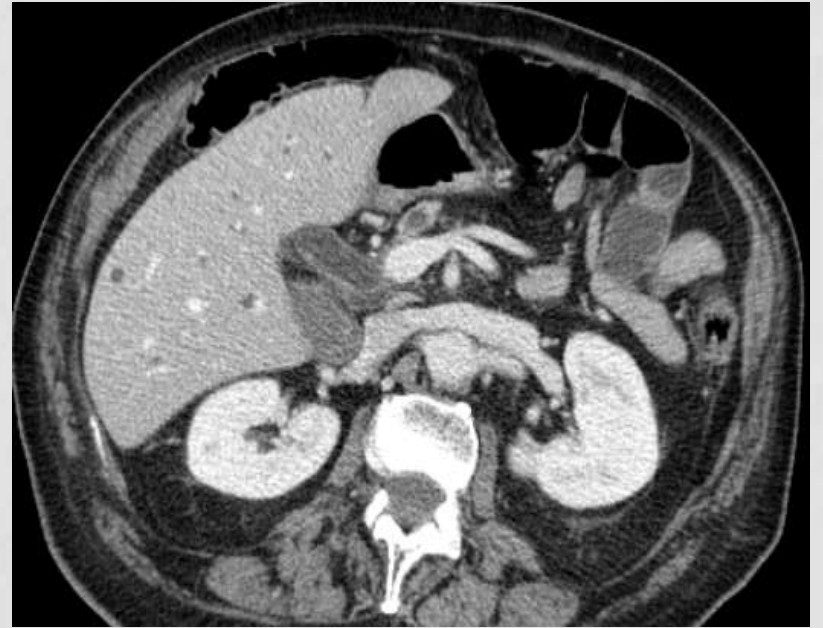
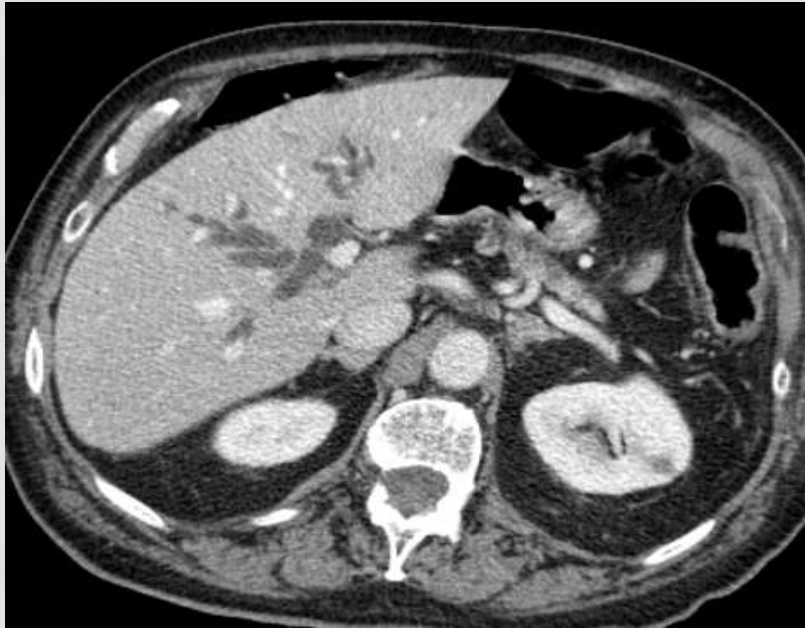- Hypovascular mass (hypoattenuating to the surrounding parenchyma)
- Focal region of homogeneous solid tissue in a fatty pancreas
- Double duct sign
 - Dilatação of the common bile duct and pancreatic duct in the absence of obstructing calculus
- Upstream pancreatic duct dilatation

CT IMAGING FINDINGS

- 10% → isoattenuating lesions
 - Focal interruption of the main pancreatic duct,
 - Dilated pancreatic and/orbiliary ducts
 - Atrophic pancreas
 - Convex contour abnormality

FOCAL ENLARGEMENT

- **Findings suggesting Adenocarcinoma vs inflammation:**
 - Vascular invasion;
 - Fewer ductal calculi;
 - **Larger caliber and more regular pancreatic duct dilatation with abrupt cutoff in the mass without the penetrating duct sign**
 - Main pancreatic duct dilatation without side branch dilatation associated with common bile duct dilatation with abrupt cutoff - **"double duct sign"**



INVITED FEATURE SECTION

Pancreatic adenocarcinoma versus chronic pancreatitis: differentiation with triple-phase helical CT

1995-2004

85 patients with pancreatic adenocarcinoma

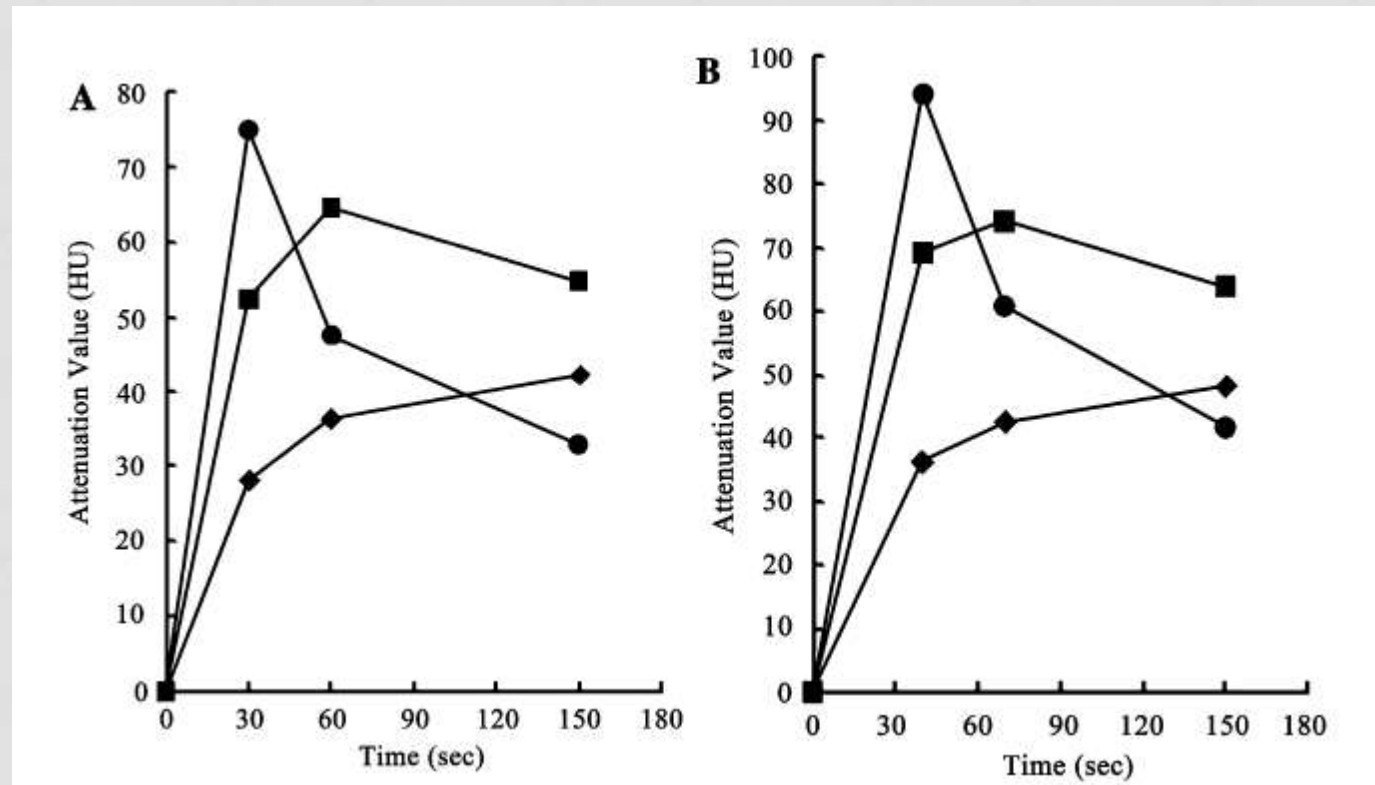
42 patients with chronic pancreatitis

Protocol A

(scan delays 30,60,150s 300mg I/mL)

Protocol B

(scan delays 40,70,150s 370mg I/mL)



Normal pancreas → early wash-out pattern (peak first phase)

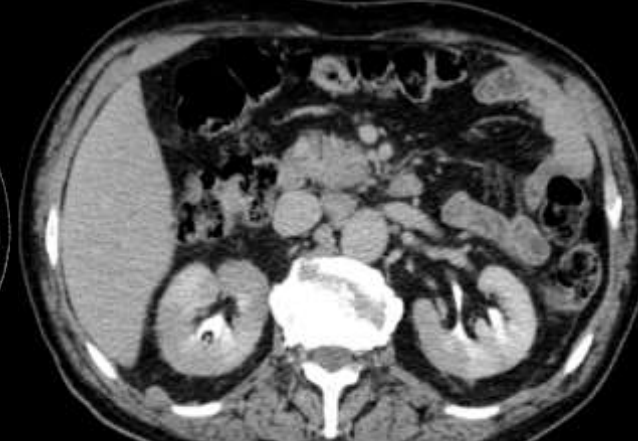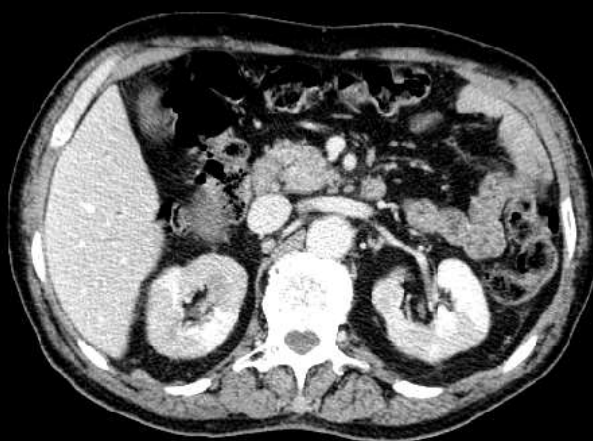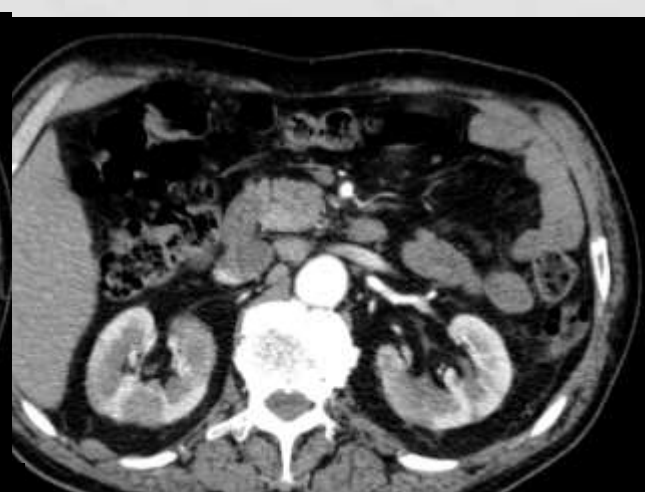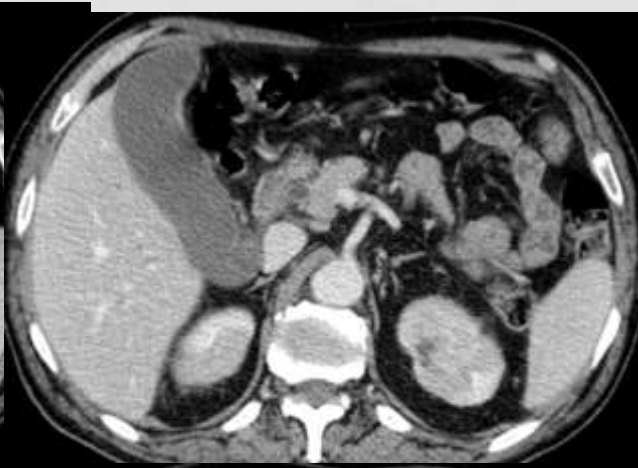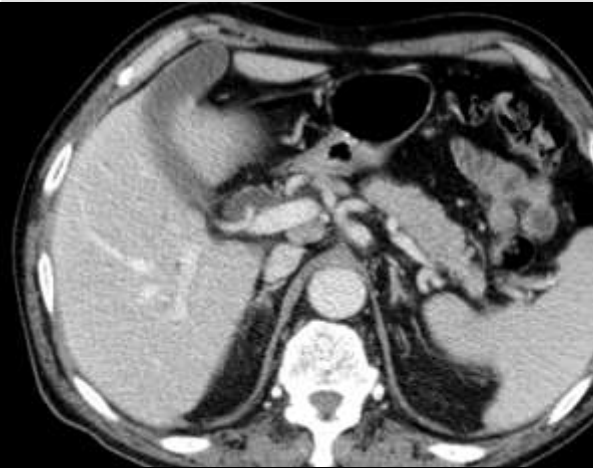Chronic pancreatitis → delayed washout pattern (peak second phase)

Pancreatic adenocarcinoma → increasing pattern

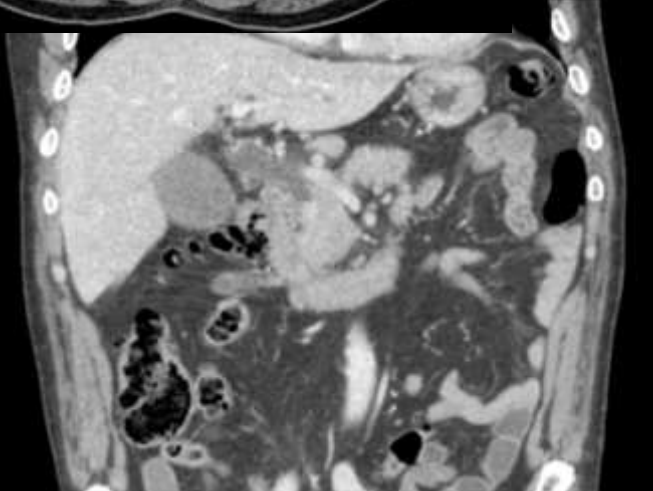
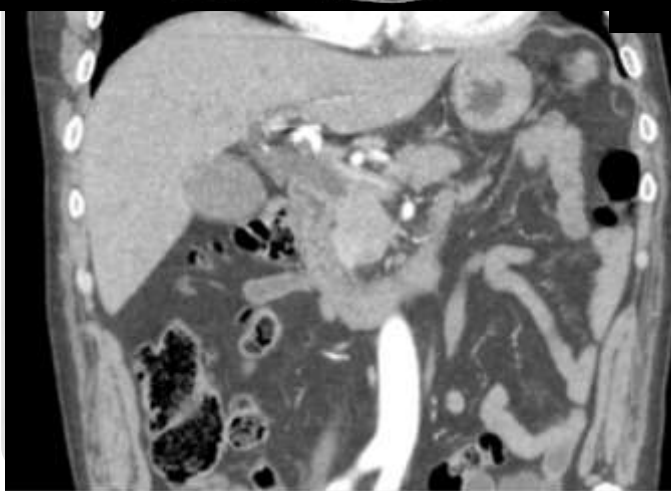
PROBLEMATIC CASES

CASE 1

- Male
- 51 years old
- Periampullary carcinoma?



Focal swelling at the pancreatic head
Slight dilatation of the common bile duct
Without pancreatic parenchymal atrophy or main pancreatic duct dilatation

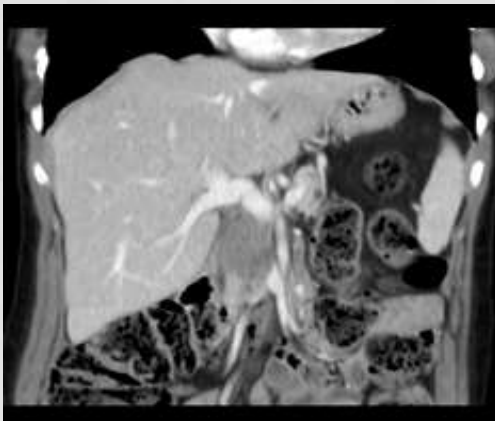
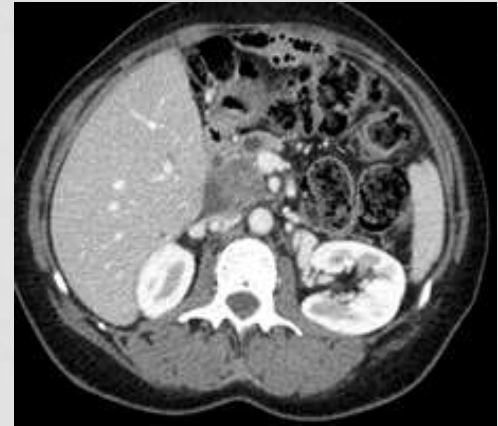
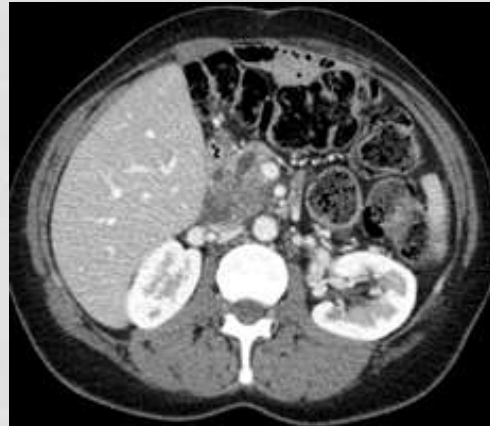
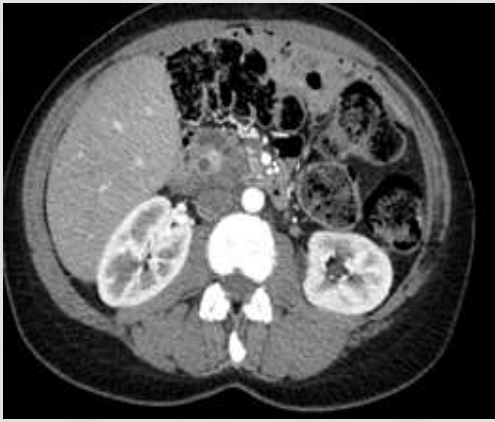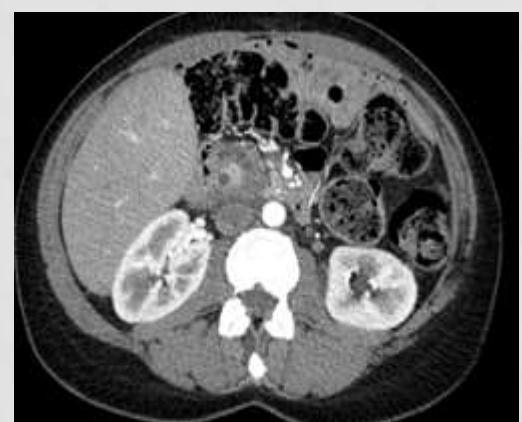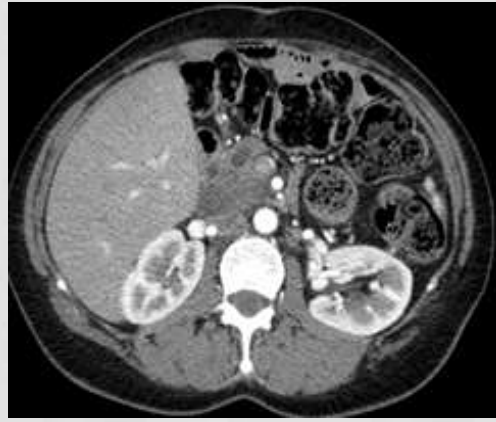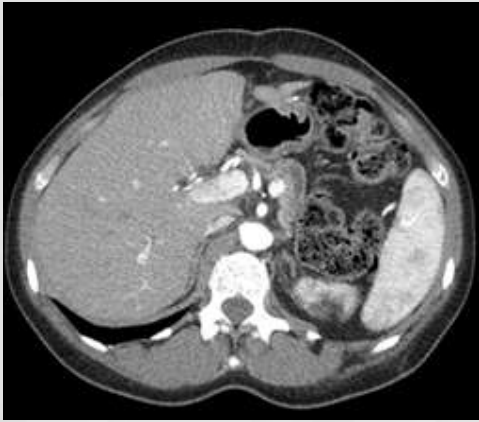AUTOIMMUNE PANCREATITIS

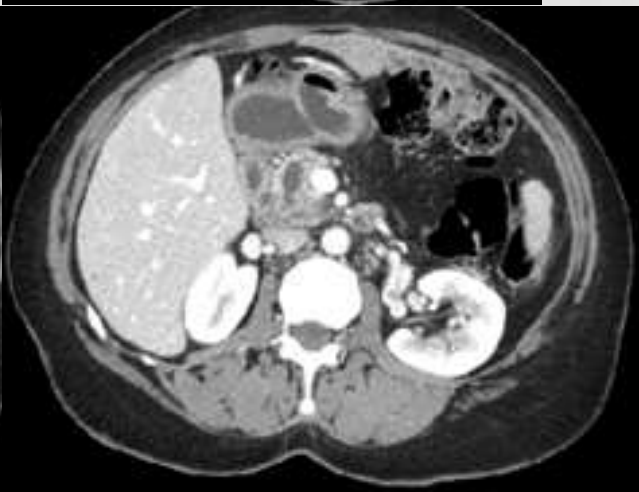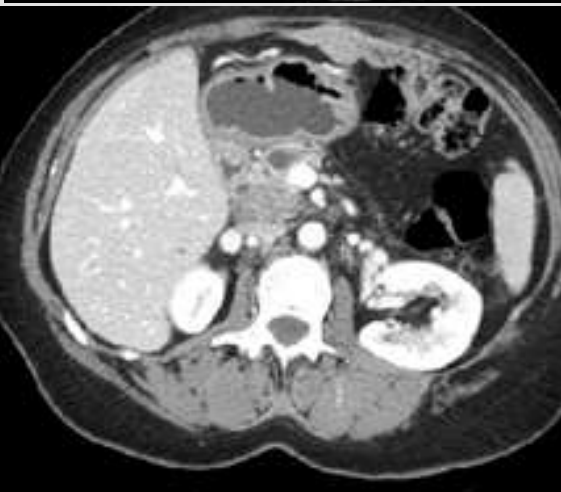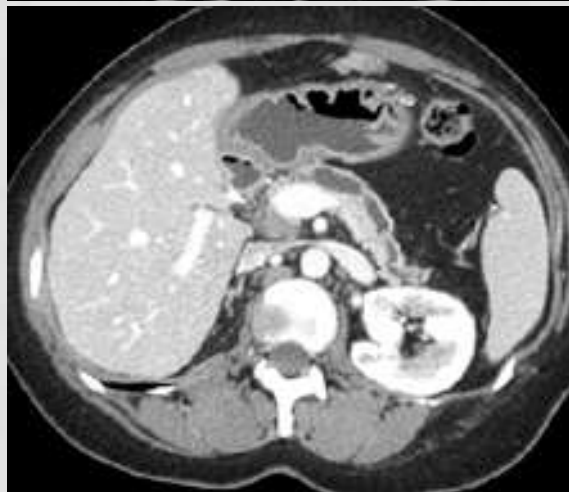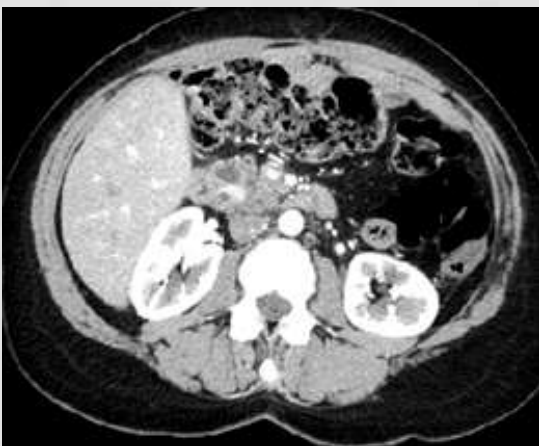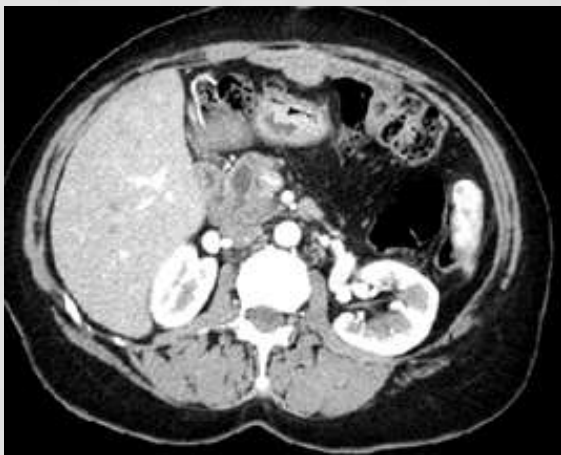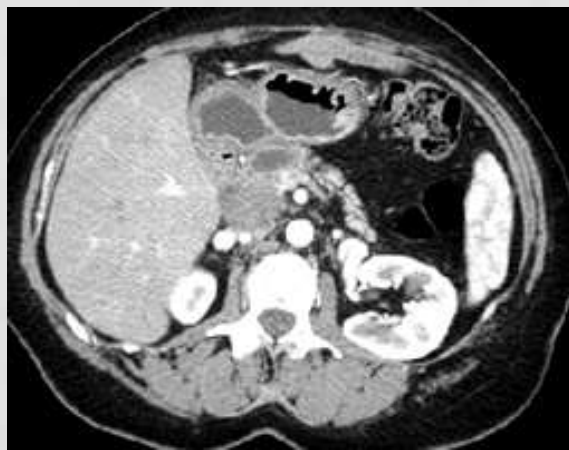- Findings suggesting autoimmune pancreatitis
 - Lack of upstream pancreatic ductal dilatation;
 - Absence of parenchymal atrophy, vascular encasement and metastasis;
 - Extrapancreatic diffuse changes related with IgG4 systemic disease

CASE 2

- Female
- 45 years old
- Follow up for “autoimmune pancreatitis” in another institution



12-03-2012



13-06-2012

CHRONIC PANCREATITIS

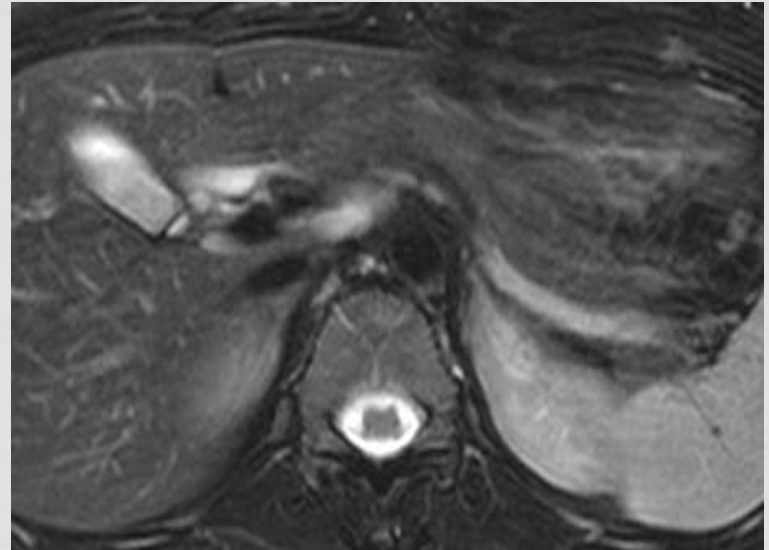
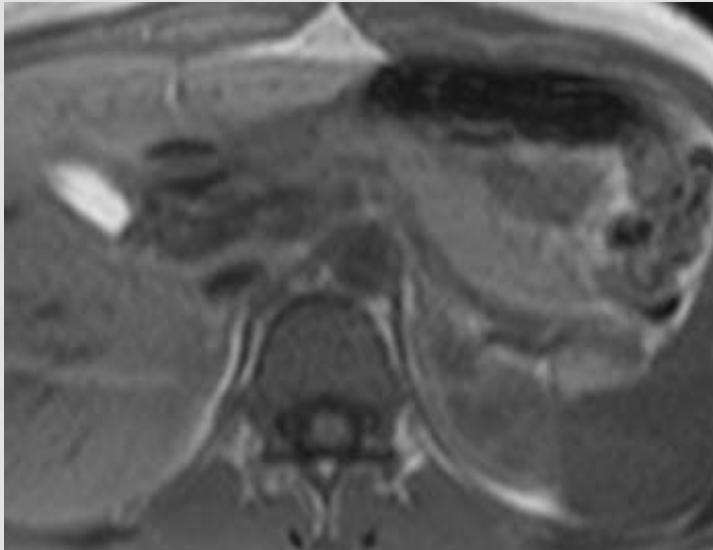
- The **ductal dilatation** is less severe and **more irregular**, with multiple ductal strictures and dilatation of side branches

MRI PROTOCOLS

- Intake of 200-500ml of water (improve the delineation of the surrounding small bowel)
- Administration of butyl-scopolamin or glucagon (reduce the peristalsis artifacts)

MR	<ul style="list-style-type: none"> • Thin slice T1 and T2-w 2D or 3D sequences (adjusted to the oblique position of the organ) with fat suppression • In-phase and opposed phase imaging • Dynamic gadolinium-enhanced T1-w imaging using a 3D fast gradient-echo sequence • DWI imaging 	<ul style="list-style-type: none"> • Assessment of pancreatic, bile ducts and cystic lesions • Assessment of pancreatic masses or focal pancreatitis • Assessment of inflammatory process, neoplasm and vascular involvement
MRCP	<ul style="list-style-type: none"> • Axial and coronal SSFSE T2-w • 3D MRCP 	<ul style="list-style-type: none"> • Assess ductal abnormalities and filling defects
Secretin-MRCP	<ul style="list-style-type: none"> • Secretin iv administration 1ml/10kg • Axial, oblique and coronal thick-slab T2-w SSFSE projections every 30s for 10-15 minutes 	<ul style="list-style-type: none"> • Better delineation of the main pancreatic duct • Improve detection of pancreatic duct variants • ↑ accuracy in detecting main pancreatic duct strictures • Indirect assessment of pancreatic exocrine reserve (secretin stimulates the production and flow of the pancreatic juice)

NORMAL PANCREAS



T1-w : presents the highest signal intensity among the organs in the upper abdomen

T2-w : intermediate signal intensity

MR FINDINGS OF DUCTAL ADENOCARCINOMA

Parenchymal findings

- Typically **low signal on T1-w and T2-w** in comparison to normal parenchyma (due to the typically very dense / fibrous stroma of the tumor)
- **Lack of enhancement of the tumor on arterial and portal phase imaging**
 - Delayed parenchymal enhancement – **possible enhancement on interstitial phase**
- These tumors frequently have **fuzzy margins**: true invasive local tumor spread vs. inflammatory desmoplastic reaction
- Necrosis can mimic the presence of a pseudocyst
- **Additional characteristics of chronic pancreatitis**

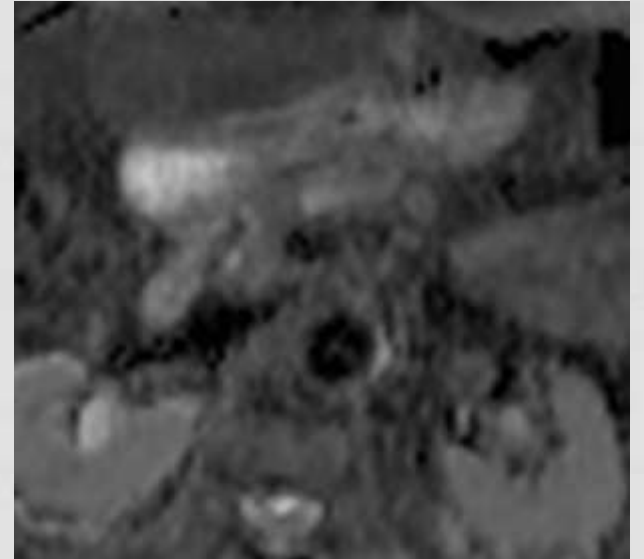
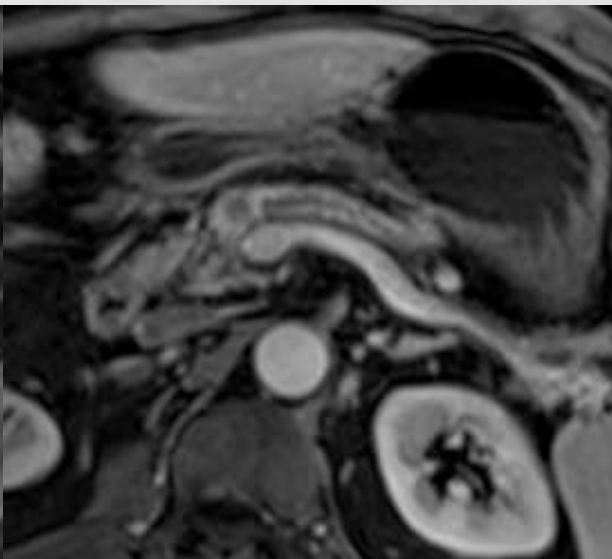
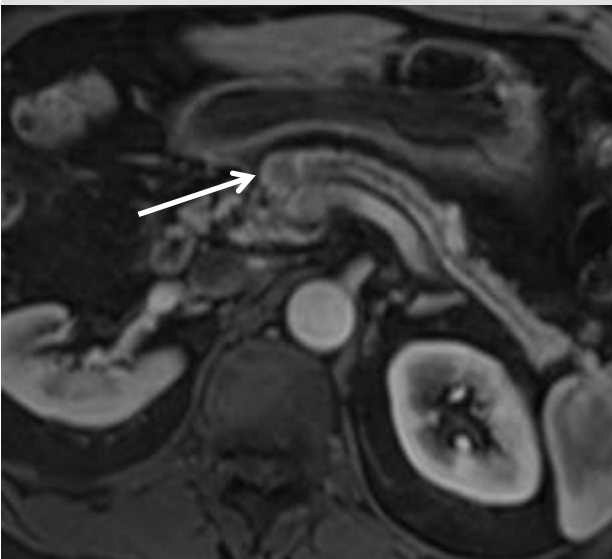

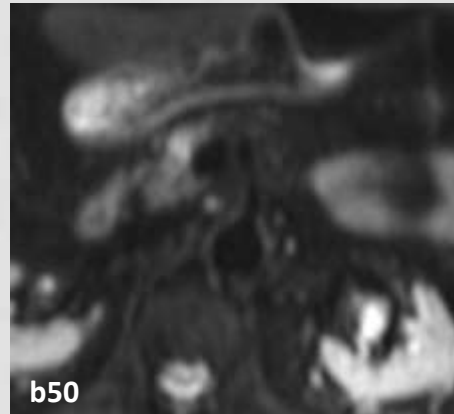
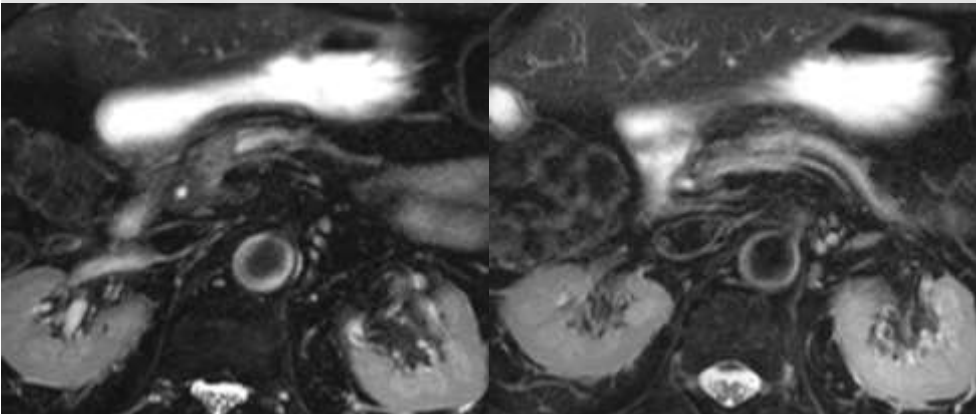
MR FINDINGS OF DUCTAL ADENOCARCINOMA

Ductal findings

- Involvement of pancreatic duct:
 - Eccentric position : **no duct dilatation**
 - Pancreatic head : can **obstruct either the pancreatic or biliary duct or both (double duct sign 5%)**
 - **Sharp cutoff of the duct with a homogeneous dilatation of the obstructed duct**

(concomitant pancreatitis is possible due to the obstruction that may impede the differential in imaging as well of biopsy specimens)

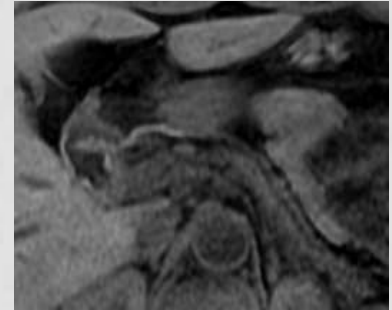
PANCREATIC ADENOCARCINOMA



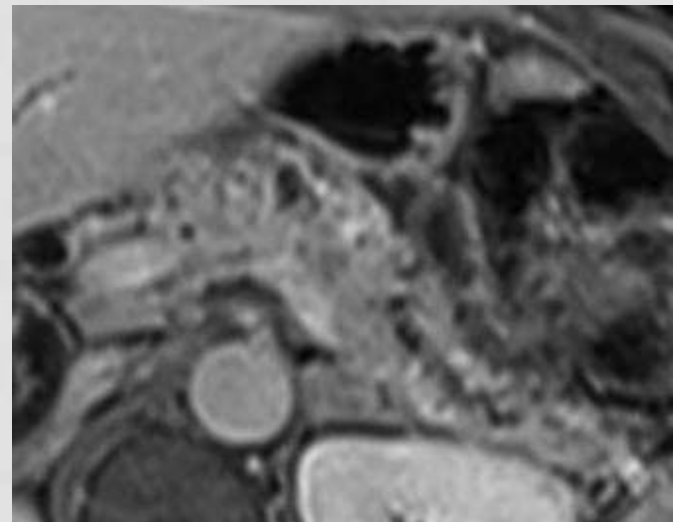
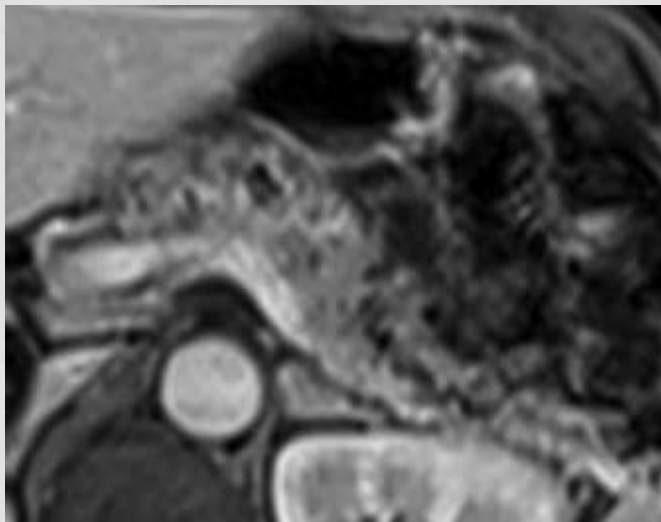
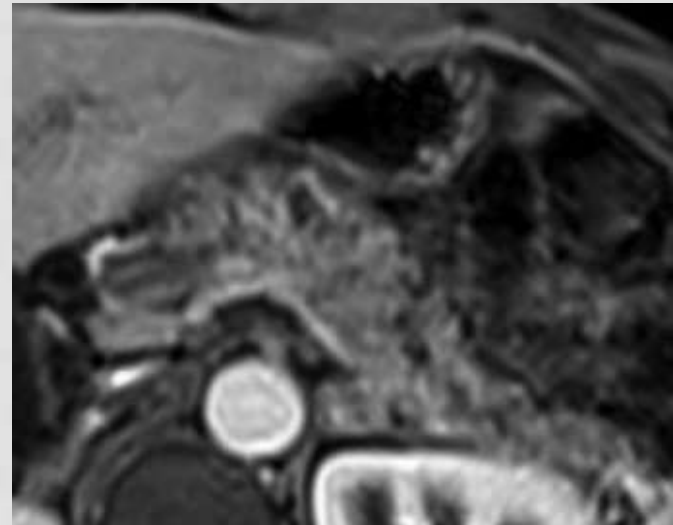
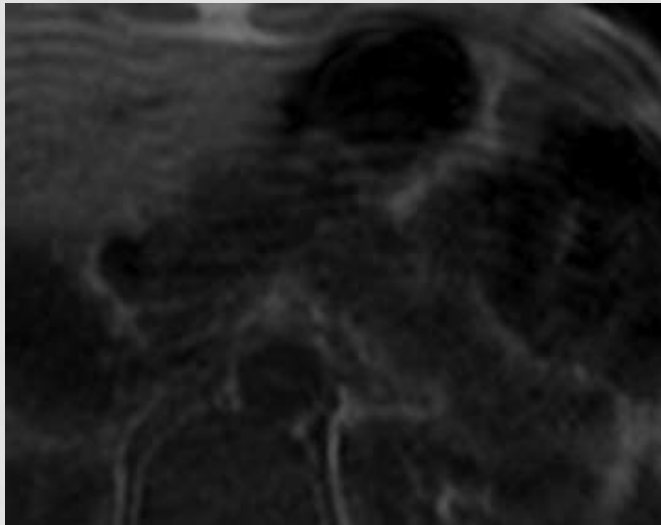
MR FINDINGS OF CHRONIC PANCREATITIS

Parenchymal findings

- **Loss of normal pancreatic hyperintense signal on FS T1-w images** (due to chronic inflammation and fibrosis leading to a decrease in the proteinaceous fluid within the parenchyma)
- **Diffuse or focal fibrosis with enlargement** – virtually indistinguishable from a pancreatic neoplasm.
- With time **atrophy** with fatty replacement will occur
- **Reduced and delayed parenchymal enhancement** (due to chronic inflammation and fibrosis - the most sensitive parameter for early diagnosis)
- **Parenchymal calcifications and small cystic changes**



MR FINDINGS OF CHRONIC PANCREATITIS



MR FINDINGS OF CHRONIC PANCREATITIS

Ductal changes

Early stage:

- **Dilatation and irregularity of side branches**

Late stage:

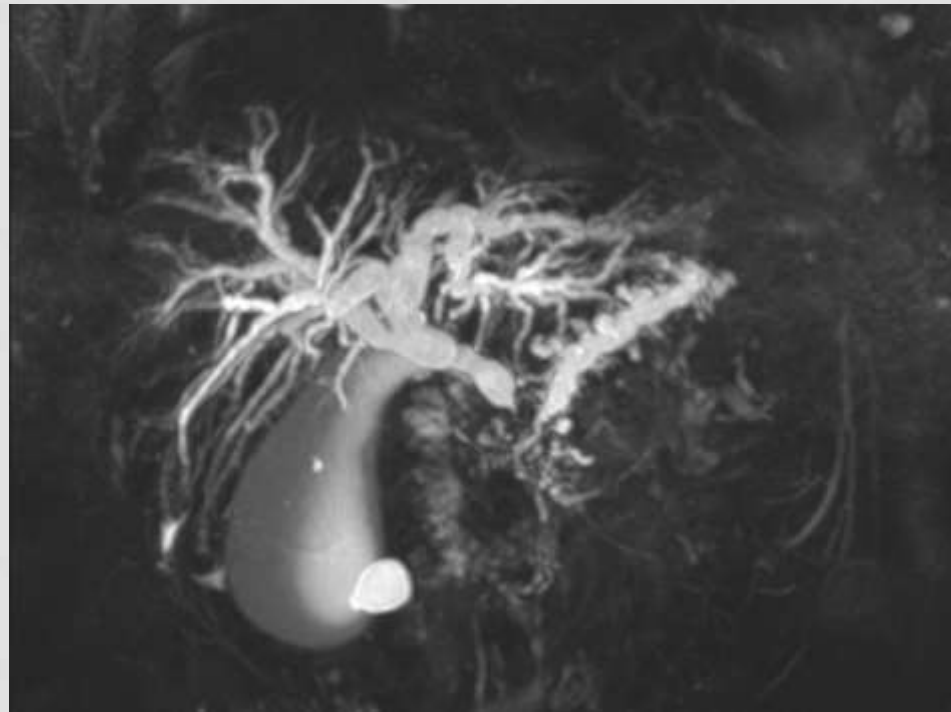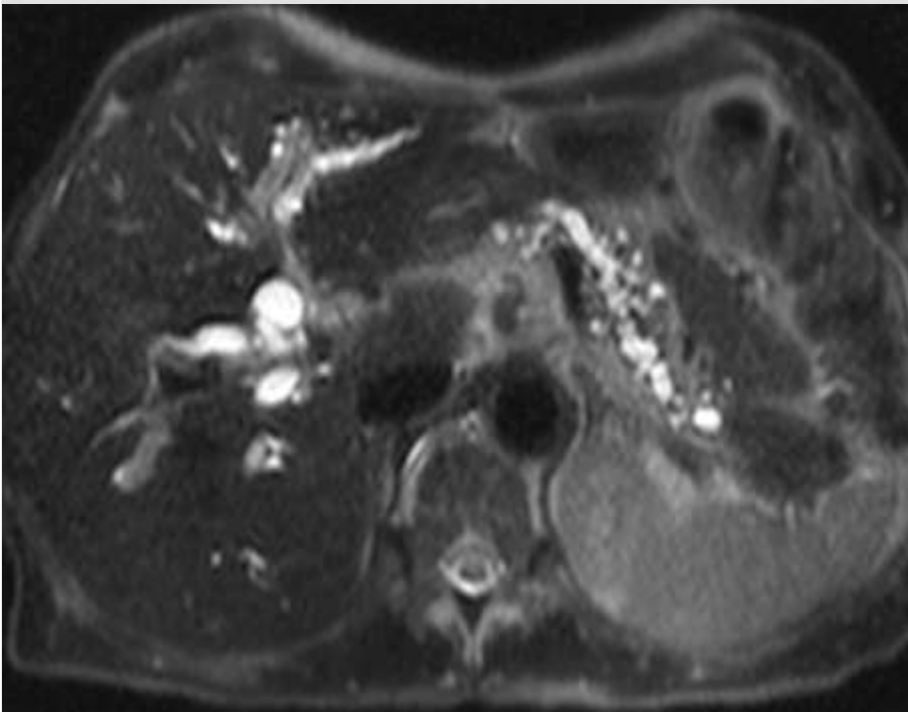
- **Dilatation and irregularity of the main pancreatic duct with strictures**

The duct is less than 50% of the pancreatic anterior-posterior diameter

- **Intraductal calcifications** (hypointense filling defects within the hyperintense fluid of the duct)

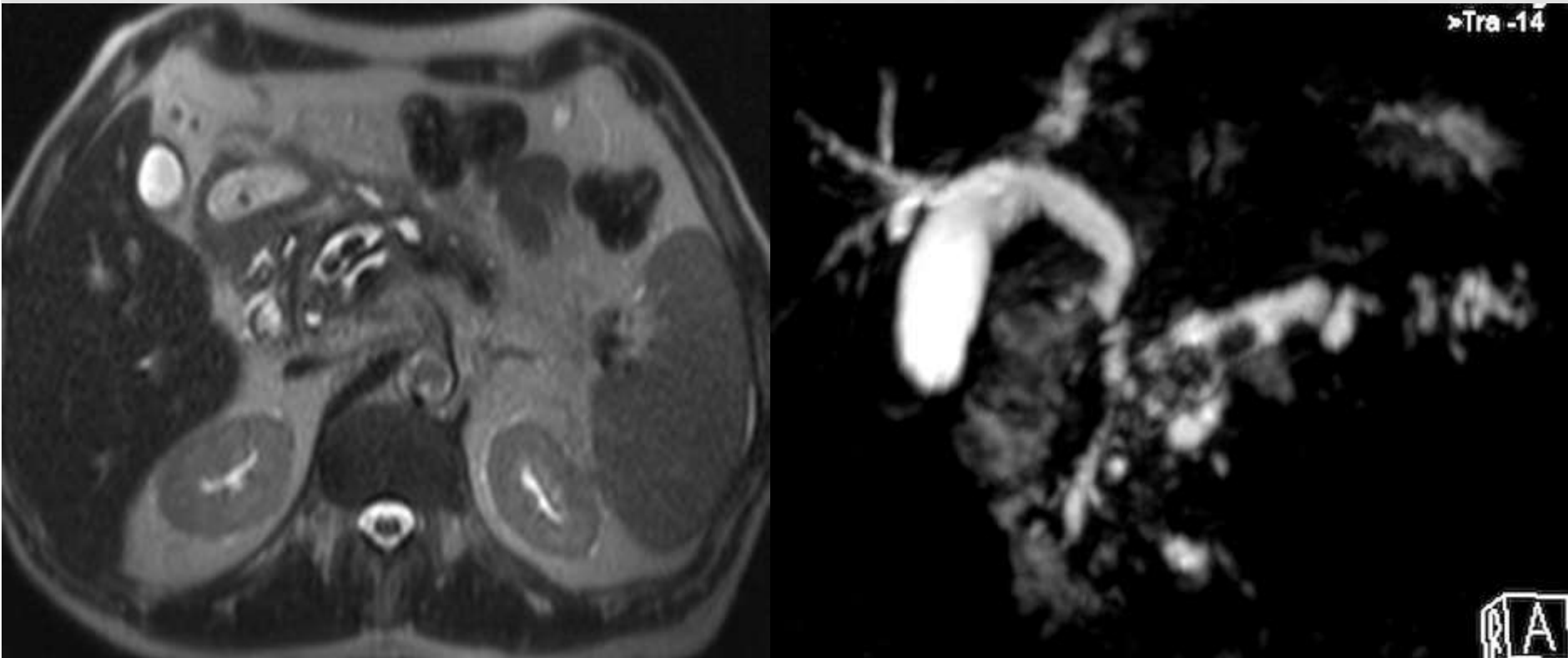
1.5-12% of cases, CP can be complicated by pancreatic cancer

MR FINDINGS OF CHRONIC PANCREATITIS



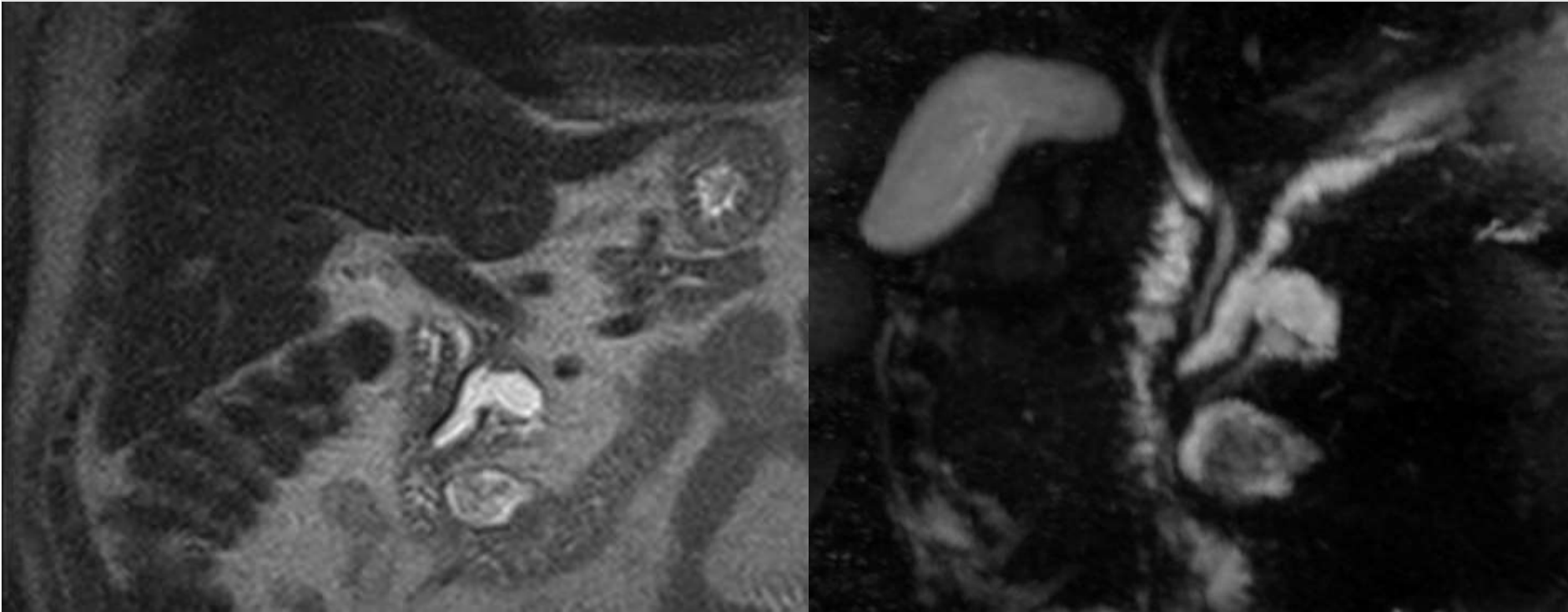
Axial FS T2-w and coronal thick-slab MRCP image, in a patient with severe chronic pancreatitis, demonstrating irregular main pancreatic duct dilatation and dilatation of several side branch ducts, with parenchymal atrophy. Bile duct dilatation is also seen.

MR FINDINGS OF CHRONIC PANCREATITIS



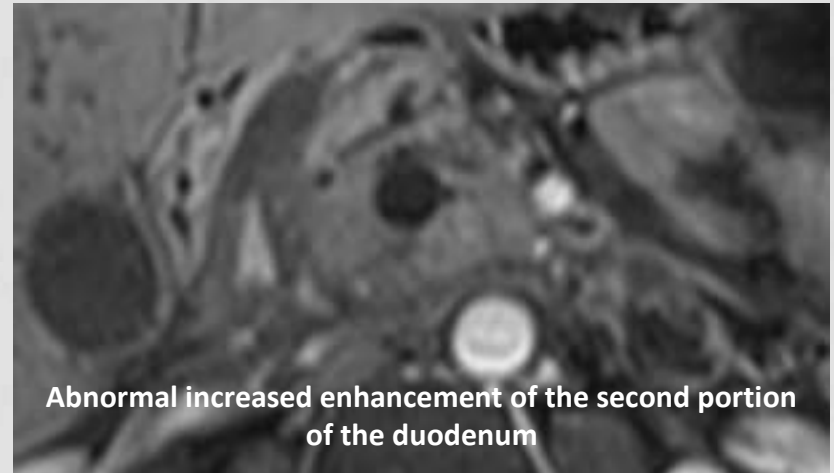
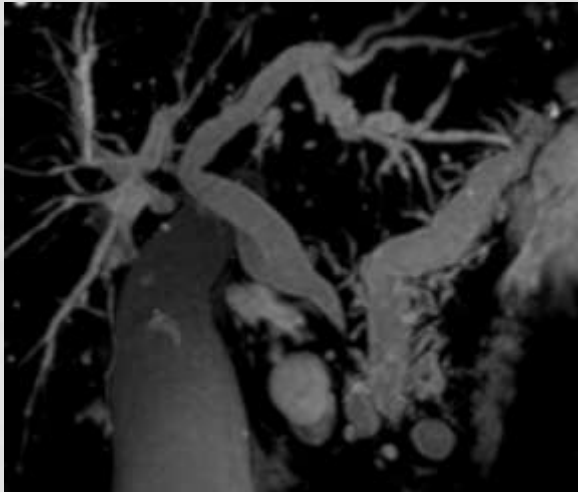
Axial HASTE and thick oblique-coronal MIP reformatted image of MRCP demonstrating irregular main pancreatic duct dilatation with two intraluminal filling defects (calcifications).

MR FINDINGS OF CHRONIC PANCREATITIS

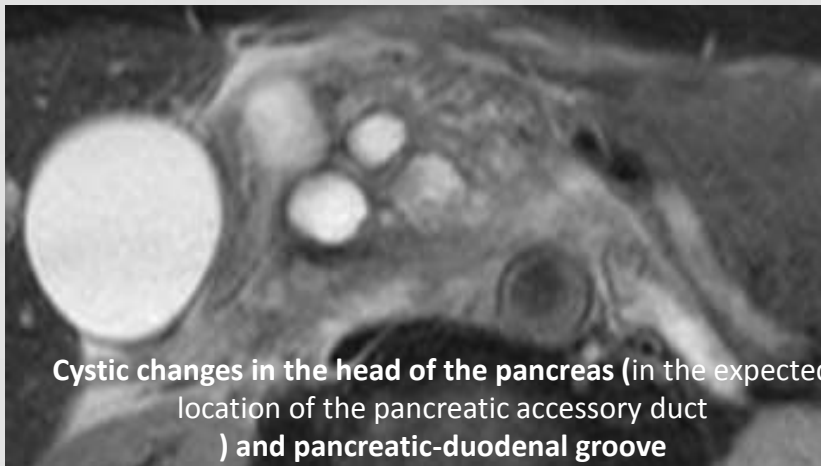


Coronal HASTE and coronal thick-slab MRCP projection of a patient with main pancreatic duct strictures and irregular dilatation with a pseudocyst in the pancreatic head communicating with the main pancreatic duct.

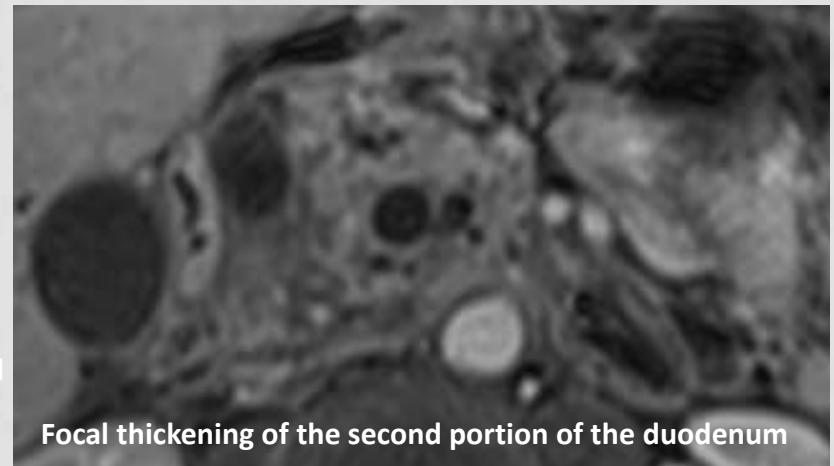
MR FINDINGS OF PARADUODENAL PANCREATITIS



Abnormal increased enhancement of the second portion of the duodenum

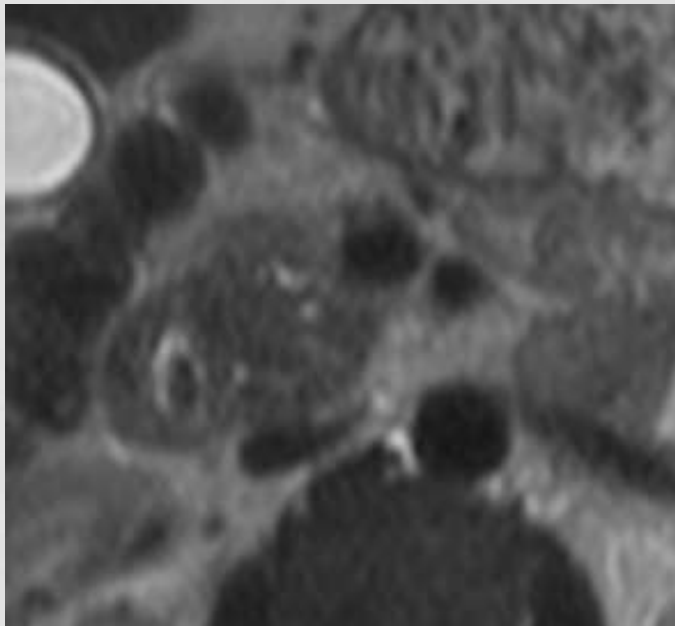
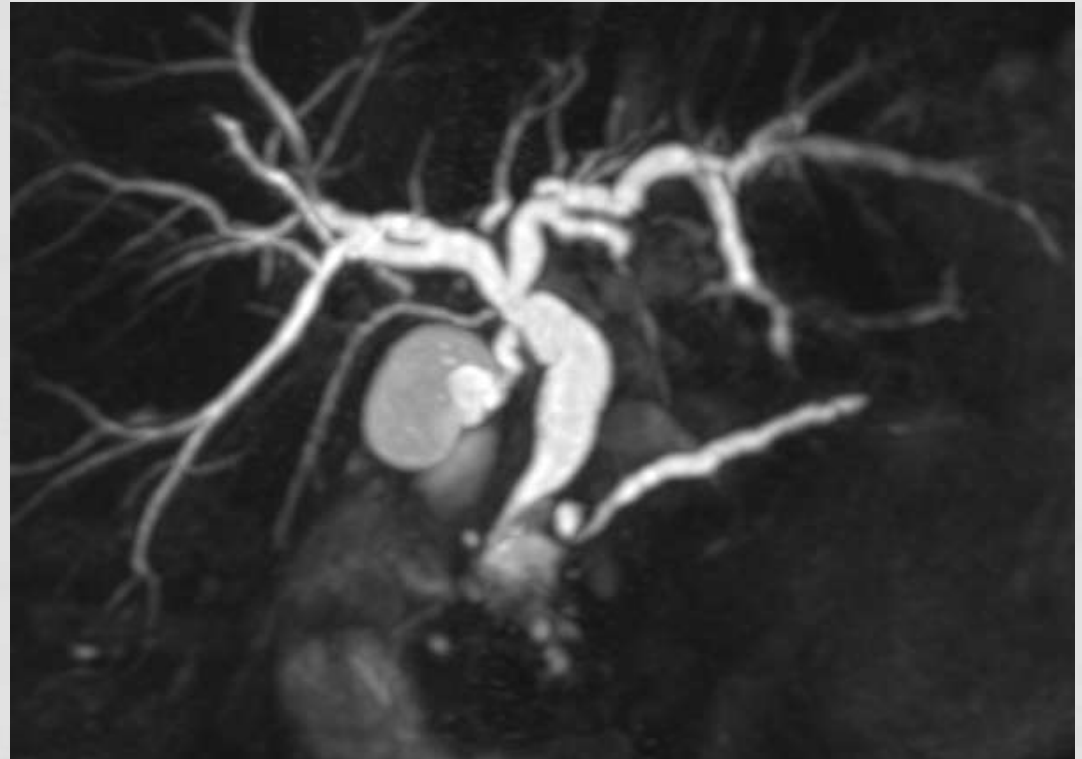
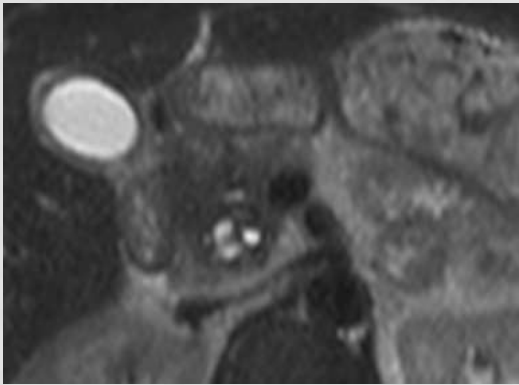


Cystic changes in the head of the pancreas (in the expected location of the pancreatic accessory duct) and pancreatic-duodenal groove



Focal thickening of the second portion of the duodenum

MR FINDINGS OF PARADUODENAL PANCREATITIS



Kalb B, Martin DR, Sarmiento JM, et al. **Paraduodenal pancreatitis: clinical performance of MR imaging in distinguishing from carcinoma.** Radiology 2013 Nov;269(2):475-81.

MRCP AND SECRETIN-MRCP ROLE IN CHRONIC PANCREATITIS

- In **early states of chronic pancreatitis MRCP is slightly less sensitive** in visualizing the dilatation and irregularity of the side branches ducts **than** endoscopic retrograde cholangiopancreatography (**ERCP**).
- **Patients with abnormal parenchymal MR imaging findings but normal MRCP may benefit from secretin-MRCP**
- **Normal pancreas:**
 - The effect starts almost immediately after secretin injection
 - Pick: 2-5 minutes after secretin injection
 - Caliber of the main pancreatic duct returns to baseline value within 10 minutes (pancreatic juice flows out through the papilla and progressively fills the duodenum)

SECRETIN-MRCP ROLE IN CHRONIC PANCREATITIS

- **Impaired response** of the pancreatic ducts at s-MRCP includes:
 - In patients with chronic pancreatitis the baseline diameter of the main pancreatic duct is larger but the **time to reach the peak diameter is longer and the percentage of increase in the diameter is low.**
 - **Prolonged dilatation of the whole main pancreatic duct** (> 3 mm at 10 min) with delayed recovery of the baseline diameter.
 - **Prolonged dilatation of side branches** and the potential occurrence of progressive increase in the signal intensity of the pancreatic parenchyma, mimicking a parenchymography.
 - **Reduced duodenal filling** (limited to the duodenal bulb) 10 minutes after secretin administration.

DIFFERENTIAL DIAGNOSIS

	CP	P-cancer
T1-w signal intensity	low	low
Ductal obstruction	+ (-)	+ (-)
Gd enhancement	↓	↓
Duct contour	irregular	smooth
Duct penetrating sign	85%	4%
Duct/Parenchyma	<0,5	>0,5
<u>Calcifications</u> (poor MRI sensitivity)	+++	-
Cysts	+++	(+) if necrotic degeneration
Lymph nodes	(+)	++
Metastases	-	+++

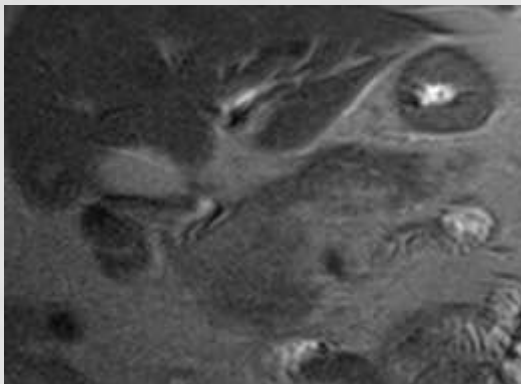
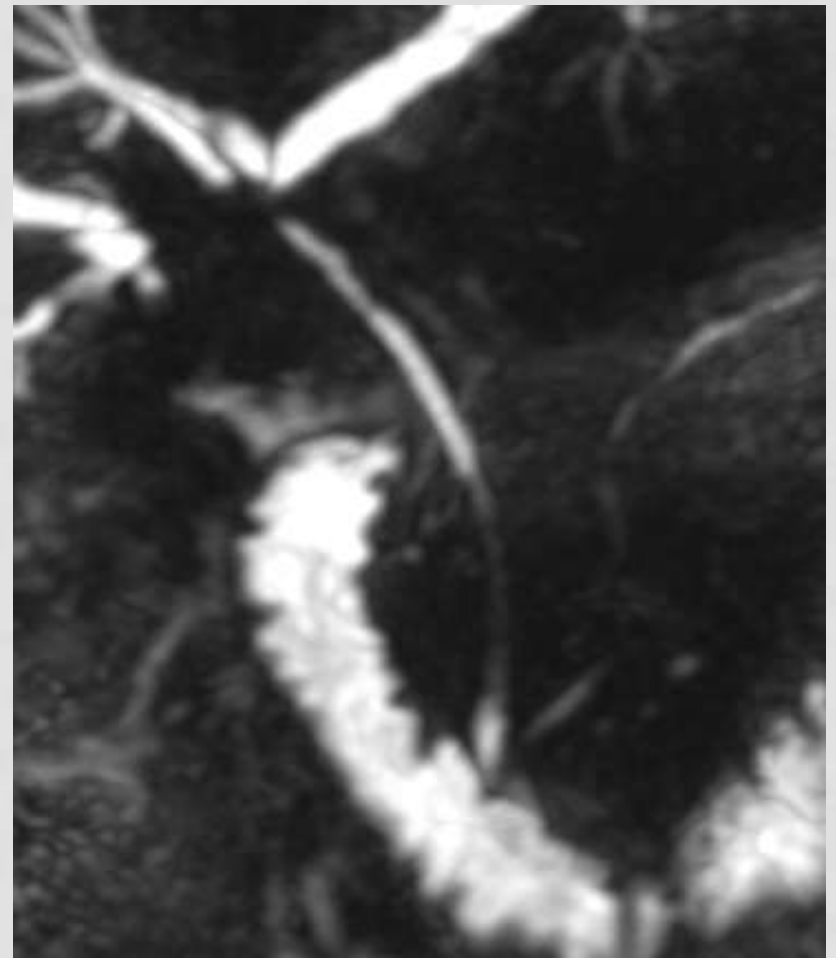
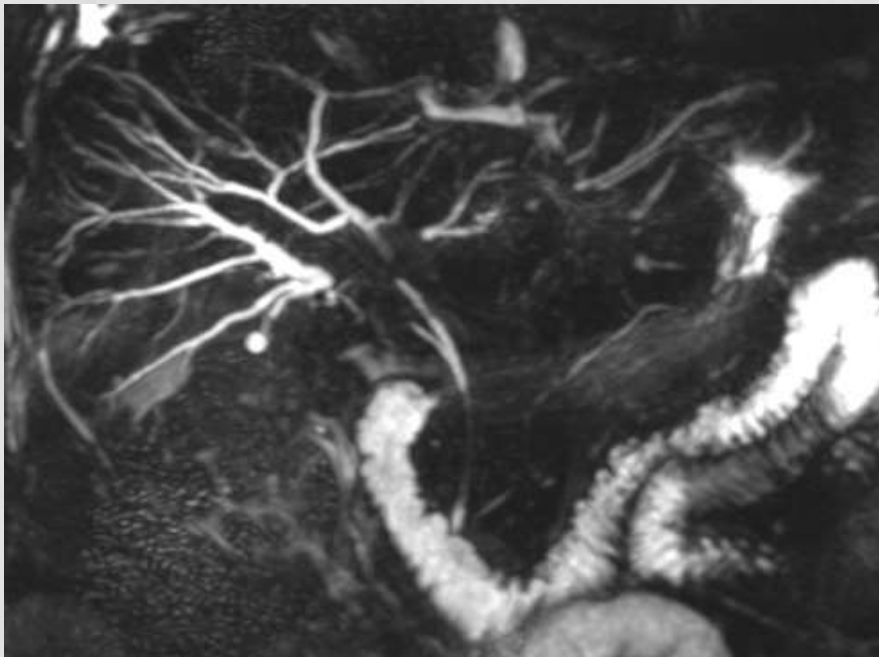
A relatively well-defined demarcation of the lesion with low signal and homogeneous poor enhancement seems to be the most discriminative finding for the differentiation of pancreatic carcinoma.

DIFFERENTIAL DIAGNOSIS WITH DUCTAL ADENOCARCINOMA

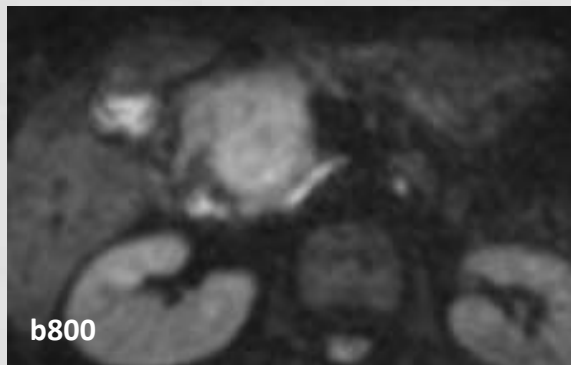
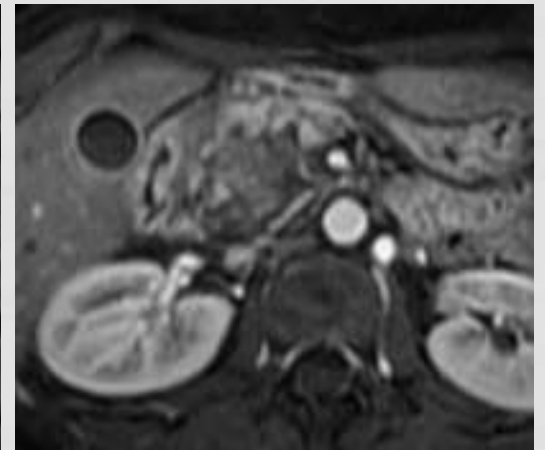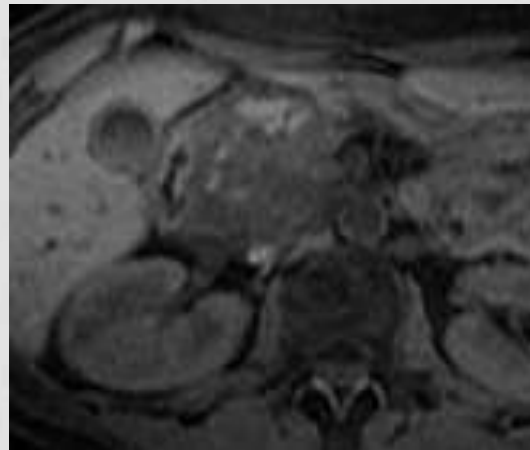
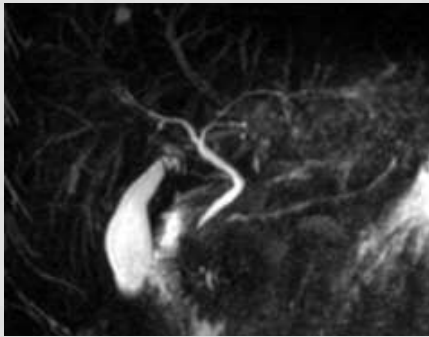
Findings suggesting chronic pancreatitis:

- Visualization of the main pancreatic duct penetrating the mass with regular stenosis – **“duct-penetrating sign”**
- The **ductal dilatation is less severe and more irregular**, with **multiple ductal strictures** and **dilatation of side branches**
- **Intraductal or scattered parenchymal calcifications**
- **Absence of clear demarcation between the focal mass and the parenchyma**
- Diffuse pancreatic involvement

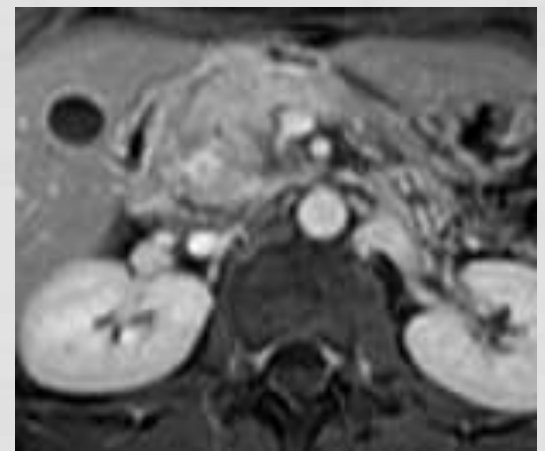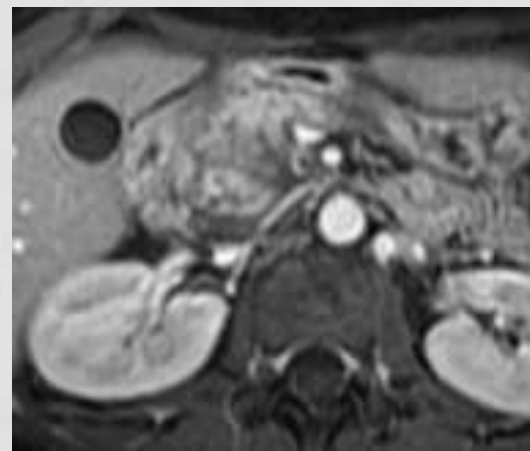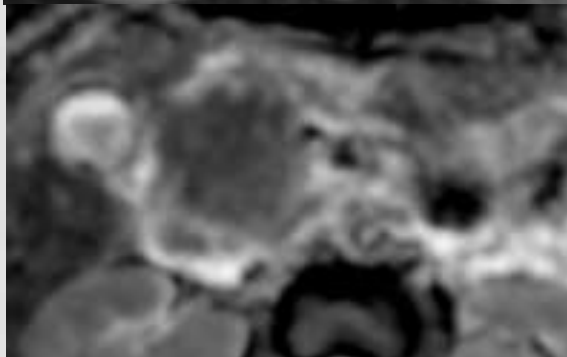
DIFFERENTIAL DIAGNOSIS WITH DUCTAL ADENOCARCINOMA



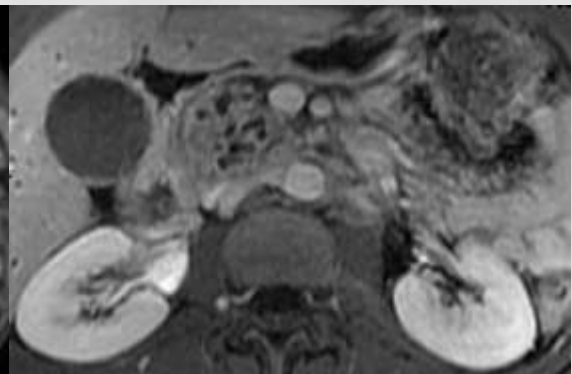
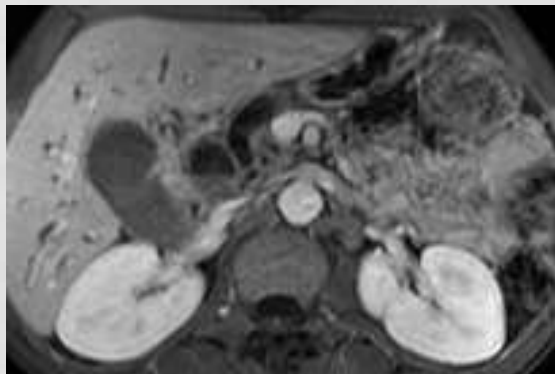
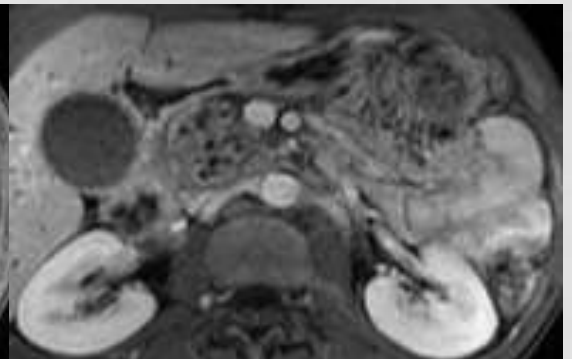
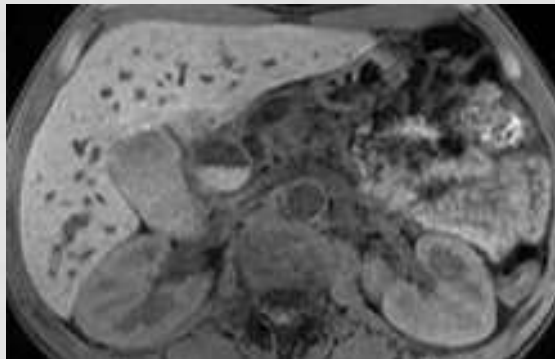
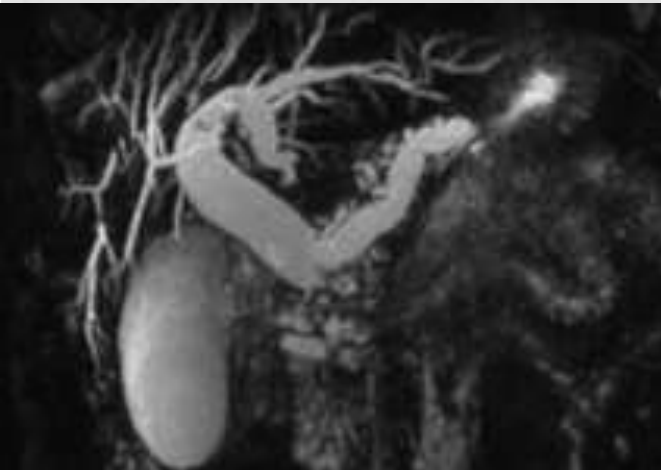FOCAL PANCREATITIS



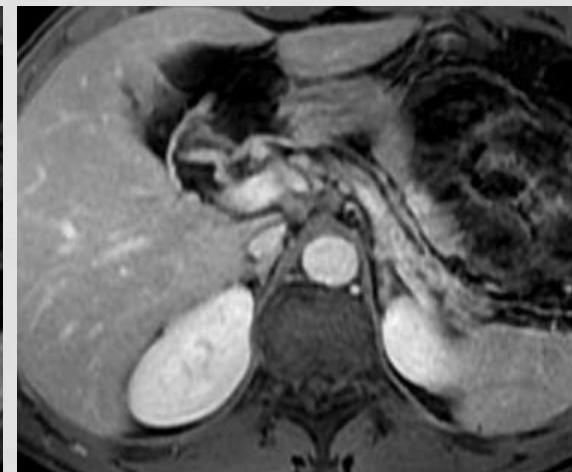
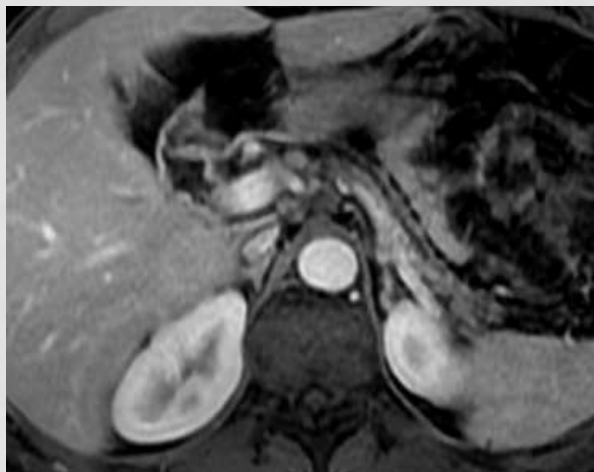
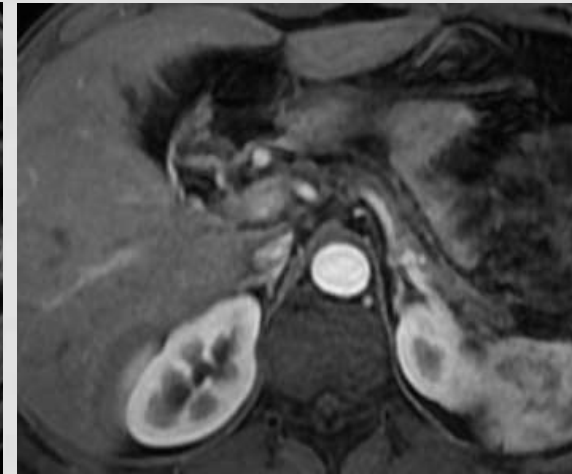
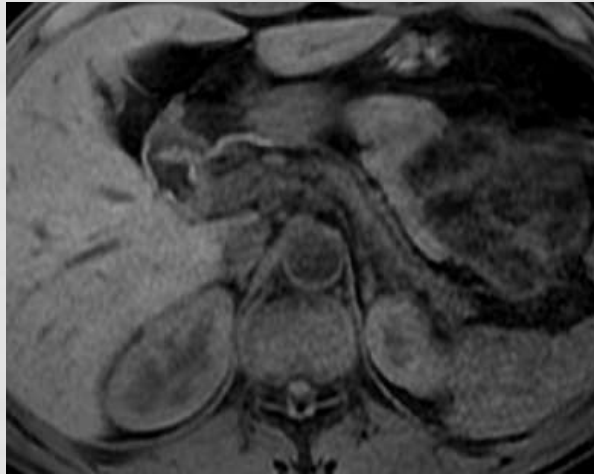
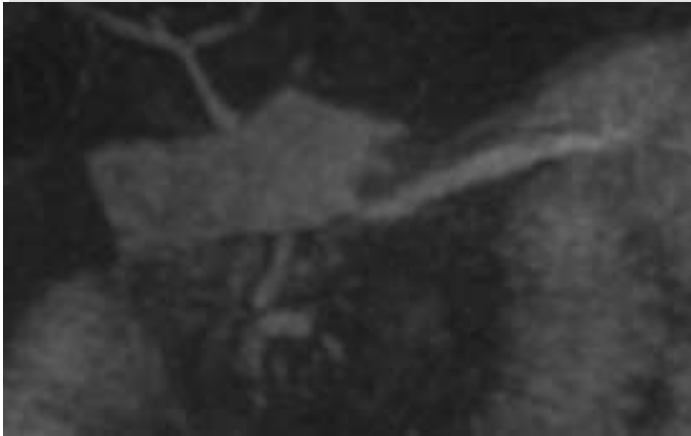b800



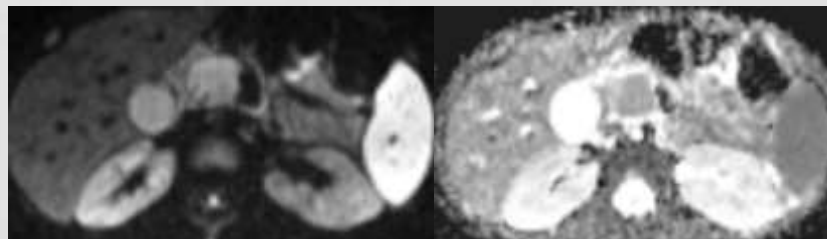
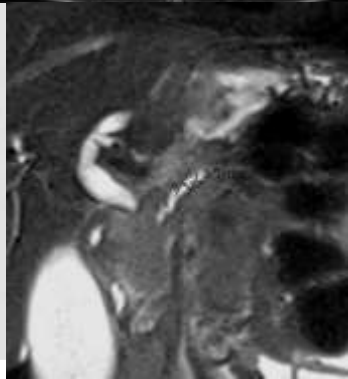
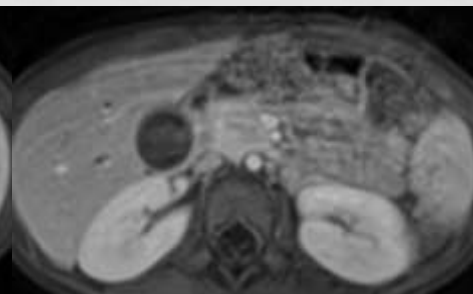
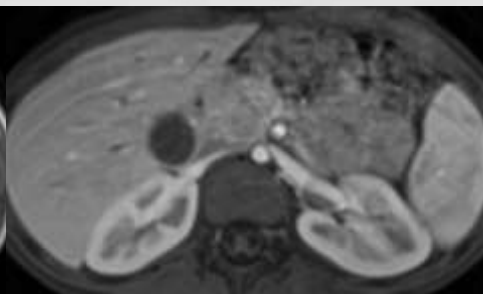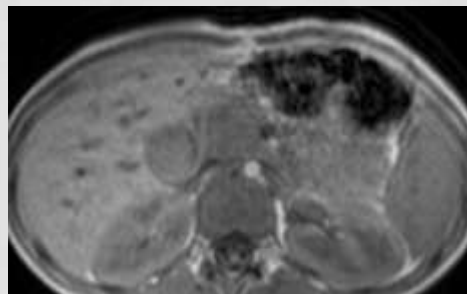
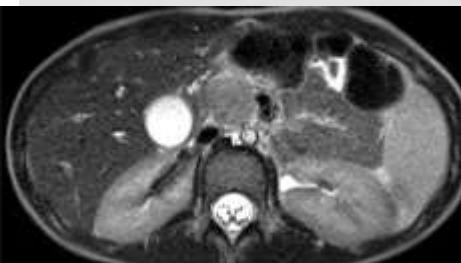
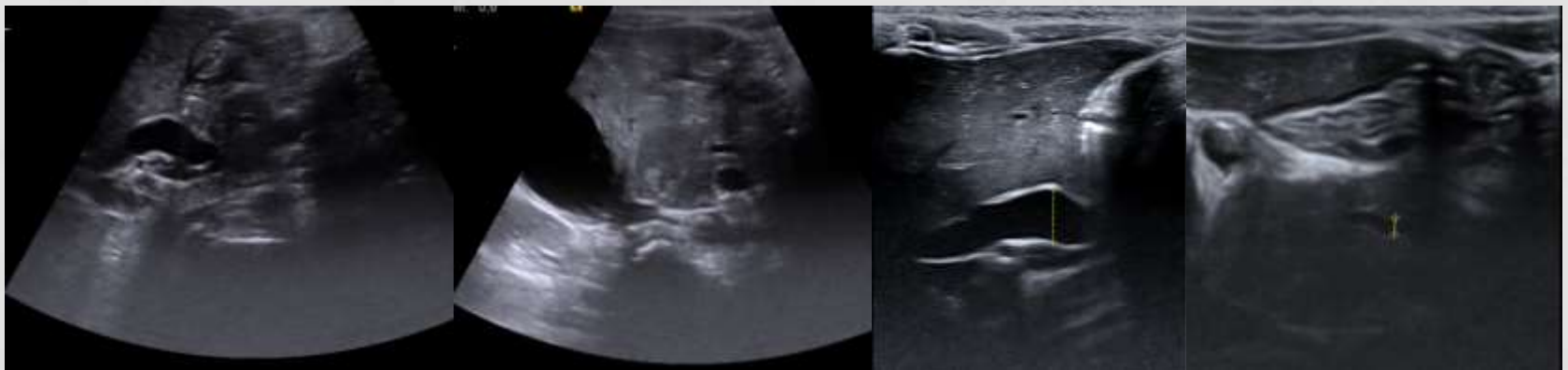CHRONIC PANCREATITIS



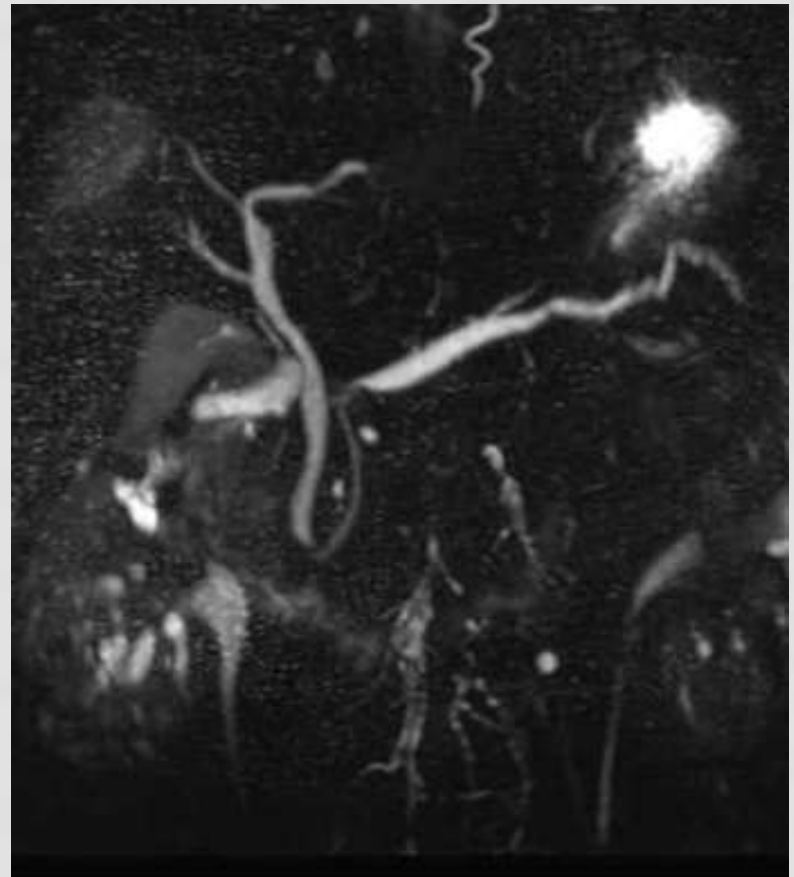
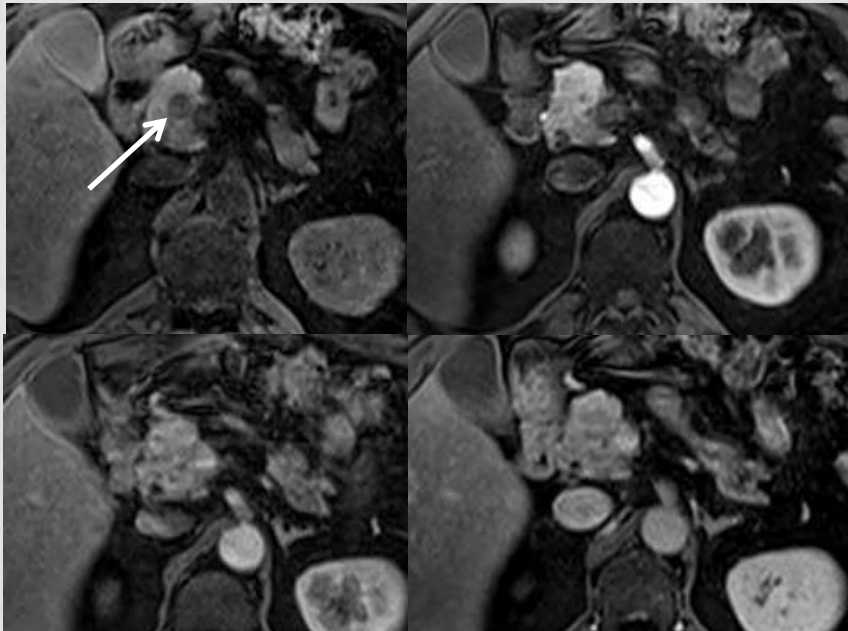
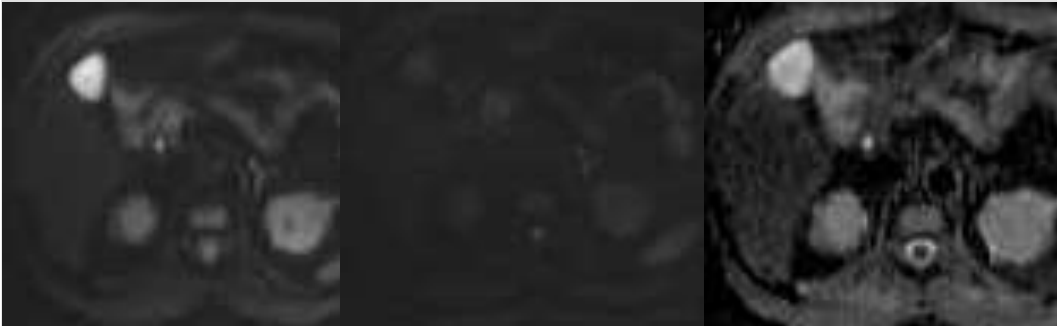CHRONIC PANCREATITIS (ATROPHY)



MASS-FORMING CHRONIC PANCREATITIS



FOCAL PANCREATITIS



DIFFERENTIAL DIAGNOSIS

- CP can cause a focal pancreatic mass indistinguishable from pancreatic carcinoma
- CP represents a major risk factor for pancreatic cancer with a 26-fold increase risk of developing it
- **The two conditions may coexist!**

Fibrotic inflammatory pseudotumor of chronic pancreatitis vs ductal adenocarcinoma
in a patient with chronic pancreatitis

**A solid mass in the pancreatic parenchyma which appears hypointense in T1-w
without significant enhancement after Gd should always be considered a neoplasm
until proven otherwise**

HOW TO DIFFERENTIATE THEM USING MRI

ADDED VALUE OF DIFFUSION WEIGHTED IMAGING (DWI)

- **ADC values are lower in patients with CP when compared with normal subjects**
 - This occurs probably due to replacement of normal parenchyma by infiltration of inflammatory cells and fibrosis, which may reduce the amount of diffusible tissue water

Lemke A, Laun FB, Klauss M, *et al.* Differentiation of pancreas carcinoma from healthy pancreatic tissue using multiple b-values: comparison of apparent diffusion coefficient and intravoxel incoherent motion derived parameters. *Invest Radiol* 2009; **44**: 769–75.

- **Both pancreatic carcinomas and MFCP were revealed as hyperintense focal lesions on DWI with a b value of 1000 s/mm²** (both these two different entities have a large amount of fibrous components).
- **The ADC value of pancreatic carcinomas was significantly lower than that of MFCP, the normal pancreas and mass-associated obstructive pancreatitis, and the ADC value of MFCP was also significantly lower than that of normal pancreas.**

Huang WC, Sheng J, Chen SY, Lu JP (2011) Differentiation between pancreatic carcinoma and mass-forming chronic pancreatitis: usefulness of high b value diffusion-weighted imaging. *J Dig Dis.* Oct;12(5):401-8

- **ADC values of the carcinomas were significantly lower compared with those of tumor-associated chronic pancreatitis and normal pancreas.**

Matsuki M, Inada Y, Nakai G *et al.* Diffusion-weighted MR imaging of pancreatic carcinoma. *Abdom Imaging* 2007; **32**: 481–3.

DIFFUSION WEIGHTED IMAGING

- **90% of pancreatic cancers show very high signal intensity on DWI, with a statistically significant difference in ADC values, as compared to that of a mass-forming chronic pancreatitis** (that usually does not show a very high signal intensity in DWI)

Takeuchi M, Matsuzaki K, Kubo H, Nishitani H (2008) High-b-value diffusion-weighted magnetic resonance imaging of pancreatic cancer and mass-forming chronic pancreatitis: preliminary results. Acta Radiol 49(4):383–386

- **MFCP mostly present with an ill-defined border due to the presence of active inflammation; pancreatic carcinomas were well demarcated from surrounding tissue on DWI when the tumor-associated pancreatitis was absent** (ill-defined if there was associated obstructive pancreatitis) and was **usually heterogeneous with non-uniform signal intensity**.

Huang WC, Sheng J, Chen SY, Lu JP (2011) Differentiation between pancreatic carcinoma and mass-forming chronic pancreatitis: usefulness of high b value diffusion-weighted imaging. J Dig Dis. Oct;12(5):401-8

DIFFUSION WEIGHTED IMAGING

- It is proposed that the weight of capillary perfusion will be decreased in ADC obtained in DWI with higher b values. **The ADC value derived from higher b value DWI provides a better sensitivity and specificity in discriminating pancreatic carcinoma from MFCP than that from low b value DWI.**

Lee SS, Byun JH, Park BJ, Park SH *et al*. Quantitative analysis of diffusion-weighted magnetic resonance imaging of the pancreas: usefulness in characterizing solid pancreatic masses. *J Magn Reson Imaging* 2008; **28**: 928–36.

- **The difference in ADC value between pancreatic carcinomas and MFCP might be attributed to their different histological features, as highly fibrotic malignancy and pancreatic carcinoma may consist of denser fibrin matrix and more intense cellular density than MFCP, and thus present with an even lower ADC value.**

Lemke A, Laun FB, Klauss M, *et al*. Differentiation of pancreas carcinoma from healthy pancreatic tissue using multiple b -values: comparison of apparent diffusion coefficient and intravoxel incoherent motion derived parameters. *Invest Radiol* 2009; **44**: 769–75.

DIFFUSION WEIGHTED IMAGING

- However, **an overlap in ADC value between pancreatic carcinoma and MFCP still remained in some cases**. This might be attributed to the variable tumor constituents in pancreatic carcinoma and the histopathological evolution of the MFCP. For example, intra-tumoral necrosis might result in increased water diffusion to varied degrees in pancreatic carcinoma.

- **ADC quantification** obtained a **sensitivity of 87.2% and specificity of 69.2%** for differentiation between pancreatic carcinoma and MFCP.

Lee SS, Byun JH, Park BJ, Park SH *et al*. Quantitative analysis of diffusion-weighted magnetic resonance imaging of the pancreas: usefulness in characterizing solid pancreatic masses. *J Magn Reson Imaging* 2008; **28**: 928–36.

- **ADC quantification** obtained a **sensitivity of 85.7% and a specificity of 86.5%** for differentiating pancreatic carcinomas from MFCP.

Huang WC, Sheng J, Chen SY, Lu JP (2011) Differentiation between pancreatic carcinoma and mass-forming chronic pancreatitis: usefulness of high b value diffusion-weighted imaging. *J Dig Dis*. Oct;12(5):401-8

DIFFUSION WEIGHTED IMAGING

- **The ADC value of PAC was significantly lower than that of NP but was not different from that of CP**

Kang KM, Lee JM, Yoon JH et al. Intravoxel Incoherent Motion Diffusion-weighted MR Imaging for Characterization of Focal Pancreatic Lesions. Radiology, 2014, Vol.270: 444-453

- **The ADC values we found for both mass-forming pancreatitis and pancreatic carcinoma are in the same range**

Klauß M, Lemke A, Grunberg K, et al. Intravoxel Incoherent Motion MRI for the Differentiation Between Mass Forming Chronic Pancreatitis and Pancreatic Carcinoma. Invest Radiol 2011;46: 57–63

The differences in ADC at high b -values are based on difference in the perfusion fraction (f), as D (true diffusion coefficient) is similar for both patient groups. The found higher ADC in mass-forming chronic pancreatitis is due to an increased f in this group.

IVIM – INTRA-VOXEL INCOHERENT MOTION

- The intravoxel incoherent motion (IVIM) model was first proposed in the late 1980s and derives from DWI, a combined measure of the molecular movement of water (diffusion) and microcirculation of blood in the capillaries (perfusion), thus providing a theoretical framework to calculate diffusion and perfusion parameters from DWI.

Le Bihan D, Breton E, Lallemand D, et al. Separation of diffusion and perfusion in intra voxel incoherent motion MR imaging. *Radiology*. 1988; 168:497–505.

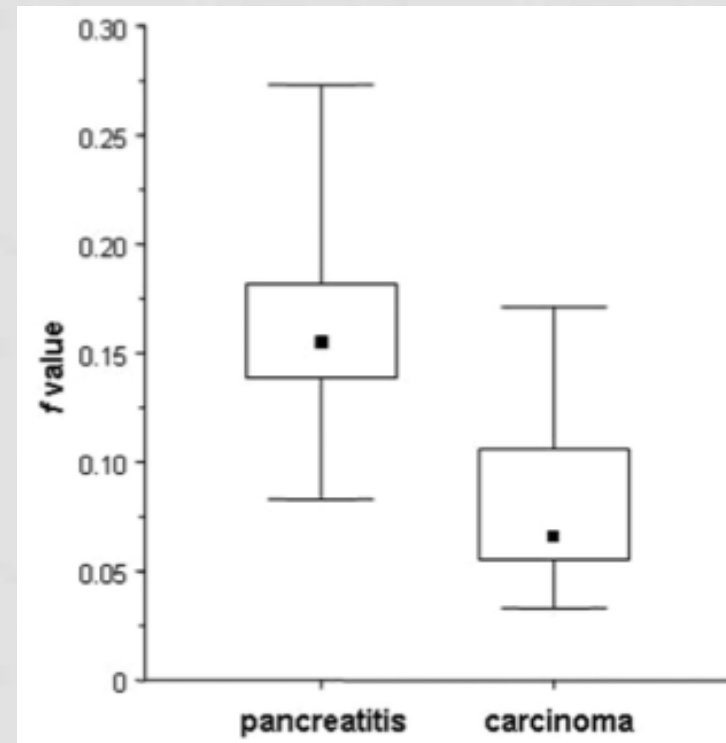
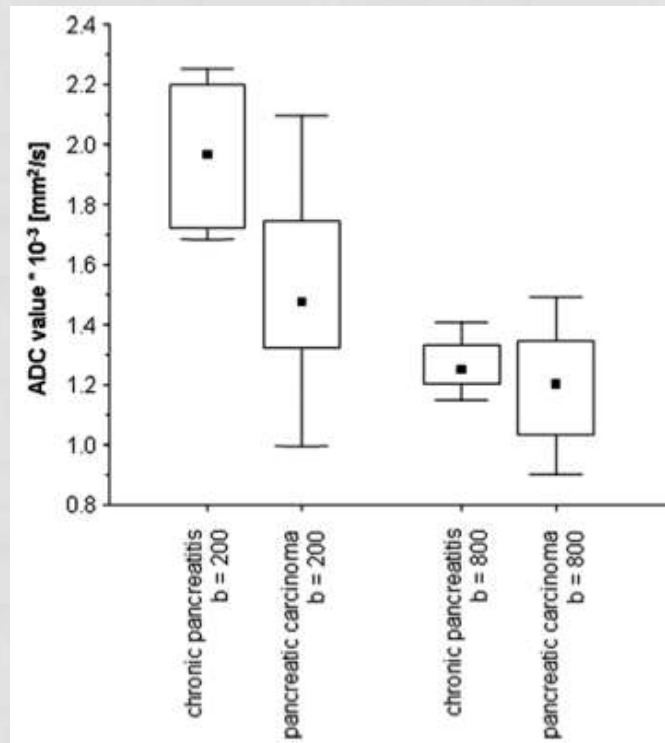
- According to this theory, the **ADC value reflects the combined effects of water diffusion and capillary perfusion in bio-tissues**, and thus it is higher than the true diffusion coefficient (D value).
- **The reduced ADC in pancreatic carcinoma reported in previous studies can be attributed to a difference in perfusion fraction which is reduced in pancreatic carcinoma**

Lemke A, Laun FB, Klauß M, et al. Differentiation of pancreas carcinoma from healthy pancreatic tissue using multiple b -values: comparison of apparent diffusion coefficient and intravoxel incoherent motion derived parameters. *Invest Radiol*. 2009;44:769–775.

Intravoxel Incoherent Motion MRI for the Differentiation Between Mass Forming Chronic Pancreatitis and Pancreatic Carcinoma

Miriam Klauß, MD,* Andreas Lemke, MSc,† Katharina Grünberg, MD,‡ Dirk Simon, MSc,§
Thomas J. Re, MD, MSc,¶ Mortiz N. Wente, MD,|| Frederik B. Laun, PhD,** Hans-Ulrich Kauczor, MD,††
Stefan Delorme, MD,‡ Lars Grenacher, MD,†† and Bram Stieltjes, MD¶

Investigative Radiology • Volume 46, Number 1, January 2011



The perfusion fraction f was significantly lower in carcinoma tissue than in chronic pancreatitis

The IVIM-derived parameter f describing the perfusion is the most sensitive parameter for the differentiation between mass-forming chronic pancreatitis and pancreatic carcinoma.

Intravoxel Incoherent Motion Diffusion-weighted MR Imaging for Characterization of Focal Pancreatic Lesions¹

Radiology

Kang KM, Lee JM, Yoon JH et al. Intravoxel Incoherent Motion Diffusion-weighted MR Imaging for Characterization of Focal Pancreatic Lesions. Radiology, 2014, Vol.270: 444-453.

- f values of PAC were significantly lower than those of NP and CP

Median Values of Measured Parameters for NP, CP, PAC, NET, and IPMN

Parameter	NP ($n = 26$)	CP ($n = 7$)	PAC ($n = 39$)	NET ($n = 17$)	IPMN ($n = 37$)	PValue*
ADC [†]	1.34 (0.91–1.67)	1.16 (1.01–1.63)	1.22 (0.66–2.20)	1.32 (0.93–2.23)	2.75 (1.33–3.67)	<.0001
$D_{\text{slow}}^{\ddagger}$	1.19 (0.81–1.51)	1.41 (1.09–1.53)	1.14 (0.53–2.07)	1.11 (0.83–1.80)	2.84 (1.24–3.94)	<.0001
$D_{\text{fast}}^{\ddagger}$	36.15 (22.60–80.30)	40.80 (24.20–57.00)	22.30 (5.70–45.00)	43.70 (24.60–75.90)	15.6 (2.10–44.50)	<.0001
f^{\ddagger}	24.79 (16.60–31.90)	18.60 (15.20–26.10)	11.60 (4.20–23.00)	29.50 (12.70–50.60)	9.65 (2.80–39.70)	<.0001

Note.—Data are median values. Numbers in parentheses are ranges.

* According to the Kruskal-Wallis test for differences in ADC and IVIM parameters between NP, CP, and pancreatic tumors.

[†] ADC, D_{slow} , and D_{fast} values are expressed as the median value ($\times 10^{-3} \text{ mm}^2/\text{sec}$), with ranges in parentheses.

[‡] f values are expressed as the median percentage, with ranges in parentheses.

IVIM – INTRA-VOXEL INCOHERENT MOTION

- The **histologic findings** comparing the vascularity of chronic pancreatitis and pancreatic carcinoma, revealed that **the pancreatitis group showed a higher vascular density when compared with the carcinoma group.**

Rzepko R, Jaskiewicz K, Klimkowska M, et al. Microvascular density in chronic pancreatitis and pancreatic ductal adenocarcinoma. *Folia Histochem Cytobiol.* 2003;41:237–239.

Conclusion (?): The found slight higher ADC in mass-forming chronic pancreatitis is due to an increased f in this group (?).

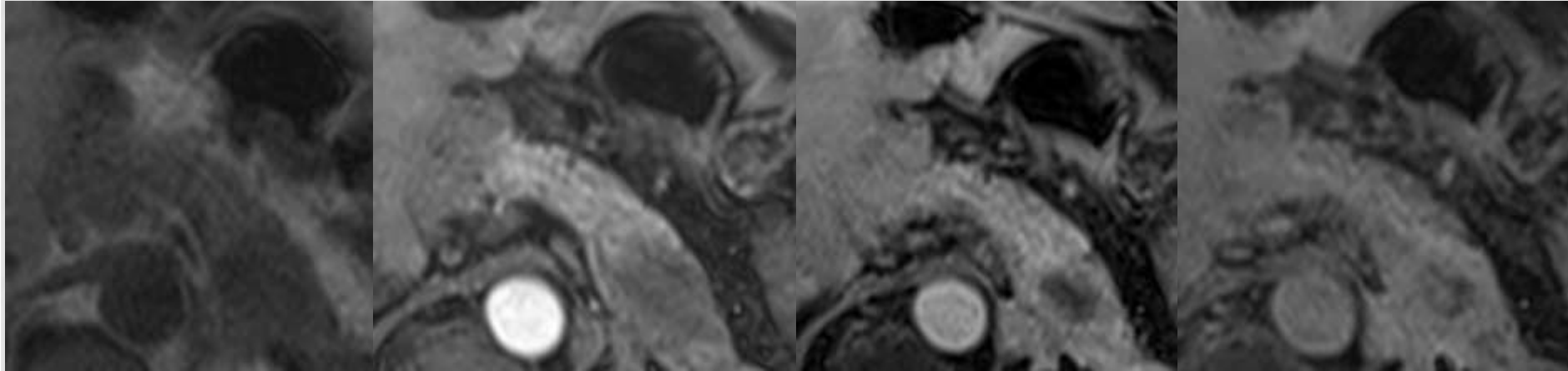
IVIM – INTRA-VOXEL INCOHERENT MOTION

- The f value was highest for normal pancreas, followed by those for neuroendocrine tumor, solid pseudopapillary neoplasm, pancreatic cancer, and mass-forming pancreatitis.
- The f value of normal pancreas was significantly higher than those of pancreatic cancer and mass-forming pancreatitis.
- However, **there was no statistically significant difference of f value between pancreatic cancer and mass-forming pancreatitis.**

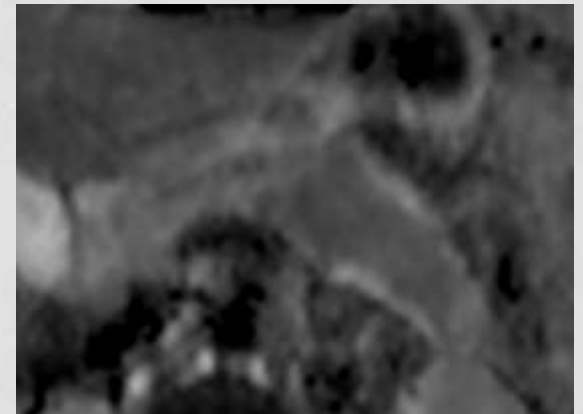
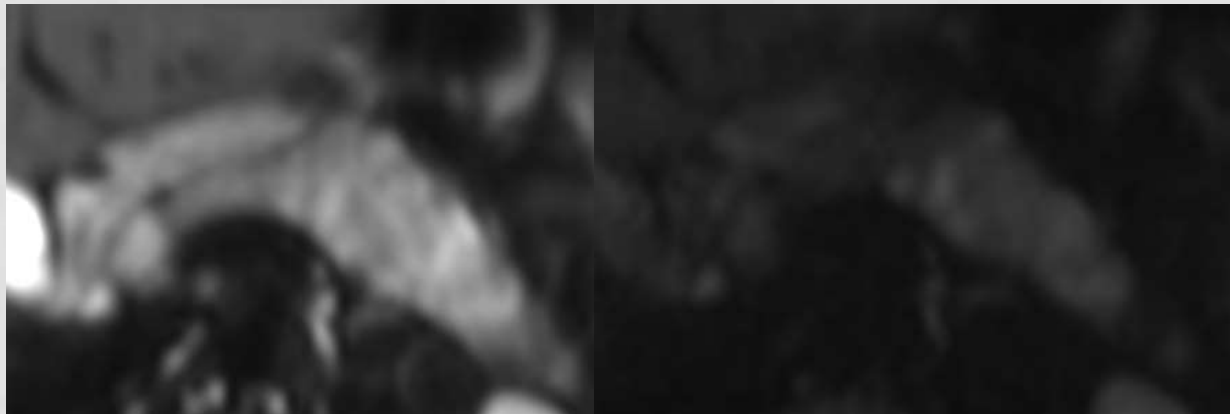
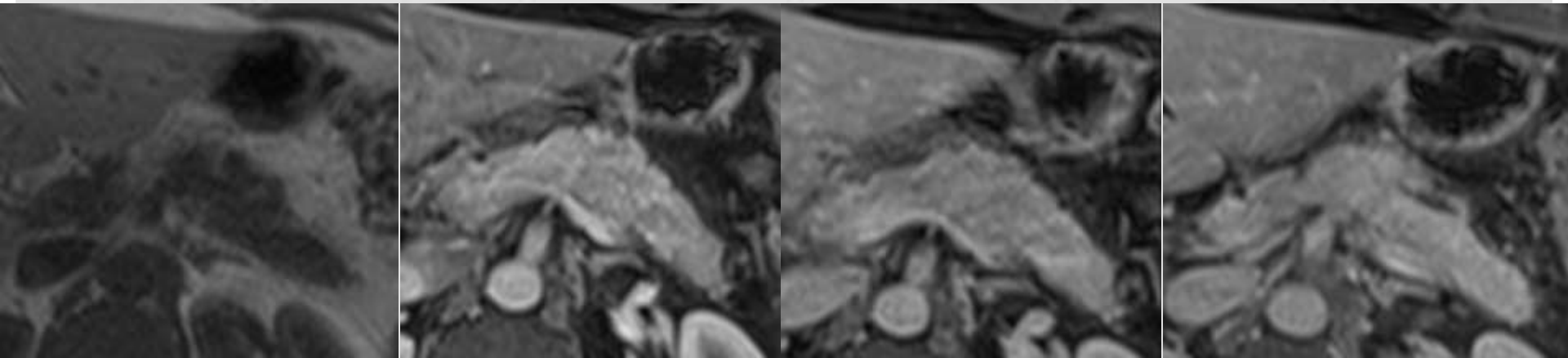
Lee SS, Byun JH, Park BJ, Park SH *et al.* Quantitative analysis of diffusion-weighted magnetic resonance imaging of the pancreas: usefulness in characterizing solid pancreatic masses. *J Magn Reson Imaging* 2008; **28**: 928–36.

Require further studies

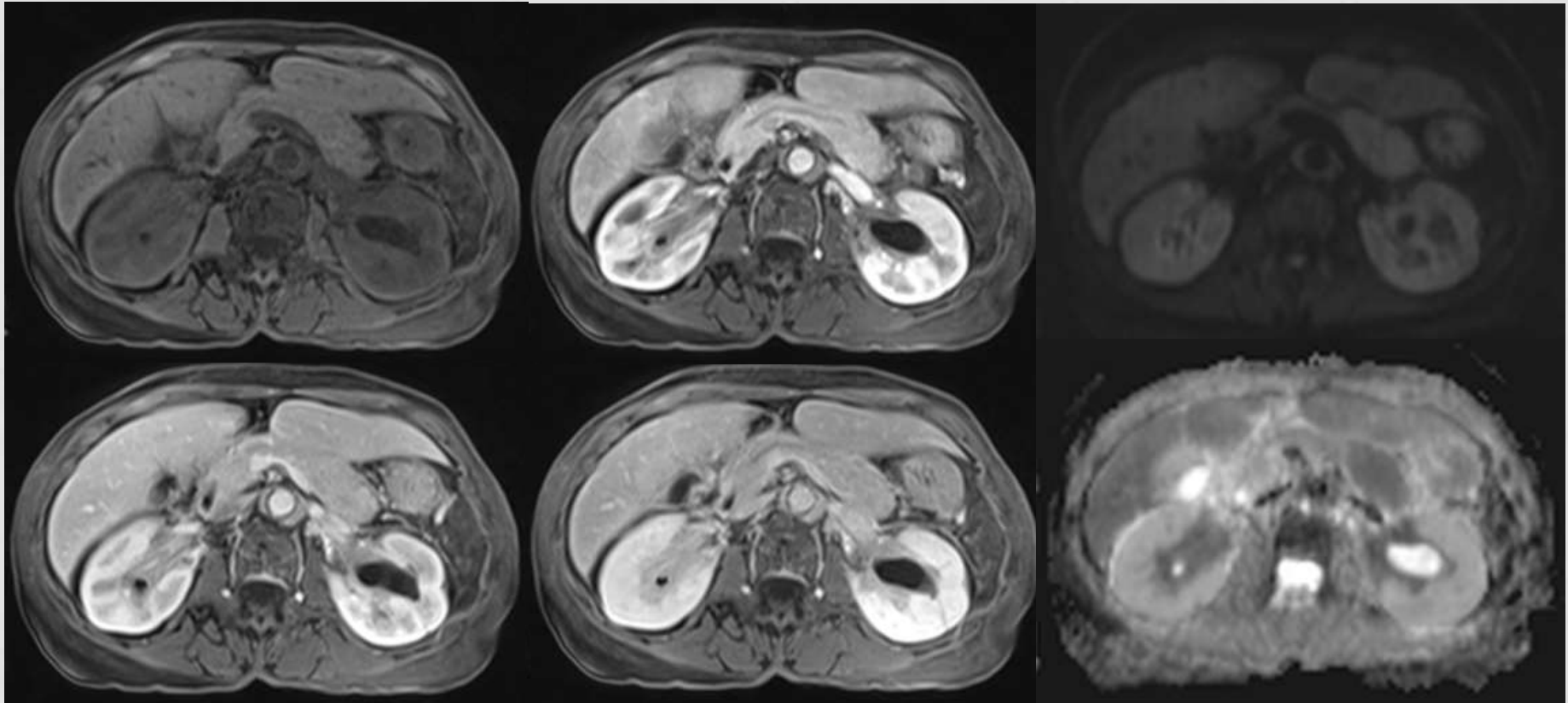
PANCREATIC ADENOCARCINOMA



CHRONIC PANCREATITIS (AUTOIMMUNE PANCREATITIS)



AUTOIMMUNE PANCREATITIS AND RETROPERITONEAL FIBROSIS



OTHER NEW TECHNIQUES

MRI SPECTROSCOPY

J Comput Assist Tomogr. 2005 Mar-Apr;29(2):163-9.

Differentiation of chronic focal pancreatitis from pancreatic carcinoma by in vivo proton magnetic resonance spectroscopy.

Cho SG¹, Lee DH, Lee KY, Ji H, Lee KH, Ros PR, Suh CH.

Author information

Abstract

OBJECTIVE: To determine the differences between the in vivo proton magnetic resonance spectroscopy (H-MRS) features of chronic focal pancreatitis and pancreatic carcinoma and to evaluate the possibility of discriminating chronic focal pancreatitis from pancreatic carcinoma by analysis of in vivo H-MR spectra.

METHODS: The H-MR spectra from 36 human pancreases were evaluated in vivo. This series included 15 cases of chronic focal pancreatitis and 21 cases of pancreatic carcinoma. All cases were confirmed histopathologically after surgical resection. The ratios of the peak area (P) of all peaks at 1.6-4.1 ppm to lipid (0.9-1.6 ppm) ($P [1.6-4.1 \text{ ppm}] / P [0.9-1.6 \text{ ppm}]$) in the chronic focal pancreatitis and pancreatic carcinoma groups were evaluated, and the results were compared. The sensitivity and specificity of the analysis were also evaluated by in vivo H-MR spectra for discriminating between chronic focal pancreatitis and pancreatic carcinoma.

RESULTS: In vivo H-MR spectra showed significantly less lipid in chronic focal pancreatitis than in pancreatic carcinoma. The ratio of $P (1.6-4.1 \text{ ppm}) / P (0.9-1.6 \text{ ppm})$ in chronic focal pancreatitis was significantly higher than that in pancreatic carcinoma ($P < 0.05$) because of a decreased peak area of lipids. The means \pm SDs of $P (1.6-4.1 \text{ ppm}) / P (0.9-1.6 \text{ ppm})$ in the chronic focal pancreatitis and pancreatic carcinoma groups were 2.78 ± 1.67 and 0.51 ± 0.49 , respectively. Using a value of <2.5 as positive for pancreatic cancer, the sensitivity and the specificity for pancreatic cancer were 100% and 53.3%, respectively.

CONCLUSION: Chronic focal pancreatitis and pancreatic carcinoma can be distinguished from each other by analysis of in vivo H-MR spectra, and in vivo H-MRS can be a useful method for making a differential diagnosis between chronic focal pancreatitis and pancreatic carcinoma.

OTHER NEW TECHNIQUES

MRI SPECTROSCOPY

PubMed

[RSS](#) [Save search](#) [Advanced](#)

Display Settings: ☐ Summary, 20 per page, Sorted by Recently Added **Send to:** ☐

Results: 7

- [Study on chronic pancreatitis and pancreatic cancer using MRS and pancreatic juice samples.](#)

1. Wang J, Ma C, Liao Z, Tian B, Lu JP.
World J Gastroenterol. 2011 Apr 28;17(16):2126-30. doi: 10.3748/wjg.v17.i16.2126.
PMID: 21547133 [PubMed - indexed for MEDLINE] [Free PMC Article](#)
[Related citations](#)
- [Discrimination of metabolic profiles of pancreatic cancer from chronic pancreatitis by high-resolution magic angle spinning 1H nuclear magnetic resonance and principal components analysis.](#)

2. Fang F, He X, Deng H, Chen Q, Lu J, Spraul M, Yu Y.
Cancer Sci. 2007 Nov;98(11):1678-82. Epub 2007 Aug 28.
PMID: 17727893 [PubMed - indexed for MEDLINE]
[Related citations](#)
- [New advances in pancreatic imaging.](#)

3. Kwon RS, Schelman JM.
Curr Opin Gastroenterol. 2008 Sep;22(5):512-6. Review.
PMID: 18891882 [PubMed - indexed for MEDLINE]
[Related citations](#)
- [Differentiation of chronic focal pancreatitis from pancreatic carcinoma by in vivo proton magnetic resonance spectroscopy.](#)

4. Cho SG, Lee DH, Lee KY, Ji H, Lee KH, Ros PR, Suh CH.
J Comput Assist Tomogr. 2005 Mar-Apr;29(2):163-9.
PMID: 15772501 [PubMed - indexed for MEDLINE]
[Related citations](#)
- [Quantitative tissue characterization in pancreatic disease using magnetic resonance imaging.](#)

5. Jenkins JP, Braganza JM, Hickey DS, Isherwood I, Machin M.
Br J Radiol. 1987 Apr;60(712):333-41.
PMID: 3580737 [PubMed - indexed for MEDLINE]
[Related citations](#)
- [Surface coil MR imaging of abdominal viscera. Part III. The pancreas.](#)

6. Simeone JF, Edelman RR, Stark DD, Wittenberg J, White EM, Butch RJ, Mueller PR, Brady TJ, Ferrucci JT Jr.
Radiology. 1985 Nov;157(2):437-41.
PMID: 4048462 [PubMed - indexed for MEDLINE]
[Related citations](#)
- [Pancreatic imaging.](#)

7. Clark LR, Jaffe MH, Choyke PL, Grant EG, Zeman RK.
Radiol Clin North Am. 1989 Sep;23(3):489-501. Review.
PMID: 2097833 [PubMed - indexed for MEDLINE]
[Related citations](#)

OTHER NEW TECHNIQUES

DCE MRI

To assess the feasibility of postprocessing dynamic contrast material-enhanced (DCE) magnetic resonance (MR) imaging timing bolus data by using a three-dimensional radial gradient-echo technique with k-space-weighted image contrast (KWIC) for the characterization of solid pancreatic diseases.

This retrospective study was approved by the institutional review board, and informed consent was waived. A total of 45 patients suspected of having biliary or pancreatic disease underwent pancreatic MR examination with a 3.0-T imager with a low-dose (2 mL gadopentetate dimeglumine) timing bolus by using the radial KWIC technique. There were 24 patients with pancreatic cancers, eight with pancreatic neuroendocrine tumors (PNETs), three with chronic pancreatitis, and 10 with a normal pancreas. By using a dedicated postprocessing software program for DCE MR imaging, the following perfusion parameters were measured for tumor and nontumorous parenchyma: volume transfer coefficient (K^{trans}) and extracellular extravascular volume fraction; the rate constant (k_{ep}) and initial area under the concentration curve in 60 seconds (iAUC) were then generated. The perfusion parameters acquired on DCE MR images were compared among the groups by using the analysis of variance test.

Solid Pancreatic Lesions: Characterization by Using Timing Bolus Dynamic Contrast-enhanced MR Imaging Assessment—A Preliminary Study¹

Volume 266: Number 1—January 2013

Seo Hyun Kim, BA
Jeong Min Lee, MD
Ji Hoon Park, MD
Soo Chin Kim, MD
Ijin Joo, MD
Joon Koo Han, MD
Byung Ihn Choi, MD

K^{trans} , k_{ep} , and iAUC values in patients with pancreatic cancer ($0.042 \text{ min}^{-1} \pm 0.023$ [standard deviation], $0.761 \text{ min}^{-1} \pm 0.529$, and $2.841 \text{ mmol/sec} \pm 1.811$, respectively) were significantly lower than in patients with a normal pancreas ($0.387 \text{ min}^{-1} \pm 0.176$, $6.376 \text{ min}^{-1} \pm 2.529$, and $7.156 \text{ mmol/sec} \pm 3.414$, respectively) ($P < .05$ for all). In addition, k_{ep} values of PNETs and normal pancreas also differed ($P < .0001$), and K^{trans} , k_{ep} , and iAUC values of pancreatic cancers and PNETs differed significantly ($P < .0001$, $P = .038$, and $P < .0001$, respectively).

Results of timing bolus DCE MR imaging with the radial KWIC sequence from routine examinations can be postprocessed to yield potentially useful perfusion parameters for the characterization of pancreatic diseases.

OTHER NEW DEVELOPING TECHNIQUES

DCE MRI

Tumoral and Nontumoral

Pancreas: Correlation between Quantitative Dynamic Contrast-enhanced MR Imaging and Histopathologic Parameters¹

Volume 261: Number 2—November 2011

Maria A. Bali, MD
Thierry Metens, PhD
Vincent Denolin, PhD
Myriam Delhaye, MD, PhD
Pieter Demetter, MD, PhD
Jean Closset, MD
Celso Matos, MD

To prospectively determine whether dynamic contrast material-enhanced (DCE) magnetic resonance (MR) quantitative parameters correlate with fibrosis and microvascular density (MVD) in malignant and benign solid pancreatic focal lesions and nontumoral pancreatic tissue.

The institutional review board approved the study; written informed consent was obtained. DCE MR was performed in 28 patients with surgically resectable focal pancreatic lesions. DCE MR quantitative parameters derived from one-compartment (OC) (transfer rate constant [K^{trans}] and distribution fraction [f]) and two-compartment (TC) (K^{trans} , tissue volume fraction occupied by extravascular extracellular space [v_e], and tissue volume fraction occupied by vascular space [v_v]) pharmacokinetic models were correlated with fibrosis content and MVD counts in focal lesions and nontumoral tissue (Spearman correlation coefficient [SCC]). Pharmacokinetic parameters were compared (Mann-Whitney test) between tumoral and nontumoral tissue. Diagnostic performance of DCE MR fibrosis detection was assessed (receiver operator characteristic curve analysis).

K^{trans} OC and K^{trans} TC were significantly lower in primary malignant tumors compared with benign lesions ($P = .023$) and nontumoral pancreatic tissue downstream ($P < .001$) and upstream ($P = .006$). f and v_e were significantly higher in primary malignant tumors compared with nontumoral pancreatic tissue downstream ($P = .012$ and $.018$, respectively). Fibrosis was correlated negatively with K^{trans} OC (SCC, -0.600) and K^{trans} TC (SCC, -0.564) and positively with f (SCC, 0.514) and v_e (SCC, 0.464), with $P < .001$ (all comparisons). MVD was positively correlated with f (SCC, 0.355 ; $P = .019$) and v_e (SCC, 0.297 ; $P = .038$) but not with K^{trans} OC (SCC, -0.140 ; $P = .33$) and K^{trans} TC (SCC, -0.194 ; $P = .181$). Sensitivity and specificity for fibrosis detection were 65% (24 of 37) and 83% (10 of 12) for K^{trans} OC (cutoff value, 0.35 min^{-1}) and 76% (28 of 37) and 83% (10 of 12) for K^{trans} TC (cutoff value, 0.29 min^{-1}), respectively.

Quantitative DCE MR parameters, derived from pharmacokinetic models in malignant and benign pancreatic solid lesions and nontumoral pancreatic tissue, were significantly correlated with fibrosis and MVD.

CONCLUSIONS

Discrimination between focal chronic pancreatitis and pancreatic adenocarcinoma is still difficult clinically, radiologically, and even histologically

- Clinical features such as abdominal pain, obstructive jaundice, and weight loss may be seen in both entities.
- Imaging results are confusing because inflammation can coexist with adenocarcinoma and adenocarcinoma may arise in long-standing chronic pancreatitis (2% of cases after 10 years and 6% after 20 years).
- Biopsy does not always help differentiate between the two entities, since they may share some common histologic features.

CONCLUSIONS

- Quantification of the *f fraction* (IVIM model) could be useful but is technically challenging and requires further studies comparing MFPC and PAC.
- DCE MRI and SMRI are promising techniques
- The rate of incorrect diagnosis is still up to 25%.

Cho SG, Lee DH, Lee KY *et al*. Differentiation of chronic focal pancreatitis from pancreatic carcinoma by *in vivo* proton magnetic resonance spectroscopy. *J Comput Assist Tomogr* 2005; **29**: 163–9.

- Secondary signs of malignancy – local or regional lymph nodes enlargement, vascular encasement, remote metastases